



**Full Length Article**

# Some Pathogenic Fungi Parasitizing Two Exotic Tropical Ornamental Fishes

Zafar Iqbal<sup>1\*</sup> and Ramsha Sajjad<sup>1</sup>

<sup>1</sup>Department of Zoology, University of the Punjab, New Campus, Lahore, Pakistan

\*For correspondence: [dr.zafariqbal.pu@gmail.com](mailto:dr.zafariqbal.pu@gmail.com)

## Abstract

The aim of this study was to investigate fungal infection in two tropical ornamental fishes koi, (*Cyprinus carpio* L.) and shubunkin (*Carassius auratus* L.). The fishes were obtained from pet shops in Lahore, Pakistan. The mean total length and mean body weight of koi (n=22) and shubunkin (n=18) were 99 mm, 11.4 g and 84 mm, 6.11 g, respectively. Koi and shubunkin showed 63.6 and 66.66% fungal infections respectively. Infected fishes had eroded scales, damaged caudal and pelvic fins, deep reddish gills and protruding eyes. Fungi isolated from infected parts of the body of the fishes were cultured on three different media; Sabouraud dextrose agar (SDA), Malt extract agar (MEA) and Potato dextrose agar (PDA). The inoculated agar plates were incubated for 5–7 days at 28–30°C. White, black, grey and green fungal colonies appeared on agar plates. Four fungal species from three genera; *Aspergillus* spp., *Mucor* sp. and *Rhizopus* sp. were isolated from both fishes. Gills were the most affected areas in koi and shubunkin with 68 and 76% infection, respectively. The posterior part of the fishes had significantly higher infection than the anterior part (P=0.05). *Aspergillus* sp. was the most prevalent (66%) fungus infecting these fishes. The three fungal genera, *Aspergillus*, *Mucor* and *Rhizopus* isolated from koi and shubunkin are considered normal mycoflora. But still they cause infection, which may result in mortality of the fish and eventually economic loss to the aquarium fish industry. © 2013 Friends Science Publishers

**Keywords:** Fish species; Fungal infection; *Aspergillus* spp.; *Mucor* sp.; *Rhizopus* sp.

## Introduction

Ornamental fish keeping is a popular hobby throughout the world. The ornamental fish trade is a multimillion dollar industry worldwide. The world export of ornamental fish was at its peak amounting to 282.6 million US\$ in 2006 (FAO, 2007). Goldfish and its varieties such as Telescope eye, Lion head, Celestial, Comet, Fantail, Veiltail, shubunkin, Bubble eye, Pearl scale, Red cap Oranda and Black moor (Ahilan *et al.*, 2009) are the most popular ornamental fish kept as pet. According to Ahmed (1996) 20 species of ornamental fishes are imported in Pakistan from Southeast Asian countries. These fishes are transported live and sold to the hobbyists at the pet shops as healthy and disease free.

In commercial fish farms and in wild huge losses of fishes and their eggs are caused by fungal infections (Bangyeekhun and Sylvie, 2001; Roberts, 2004). There may be 100% mortality of incubated eggs due to fungal infection. Fry and fish production is seriously affected by fungal infection in hatcheries and fish farms (Chukanhom and Hatai, 2004; Kwanprasert *et al.*, 2007).

Many fungal taxa are known to be pathogenic viz, *Aspergillus* Micheli (Salem *et al.*, 1989); *Achlya bisexualis* Coker and Couch (Kwanprasert *et al.*, 2007); *Saprolegnia* spp., *Aphanomyces* spp. and *Branchiomyces* sp. (Siddique

*et al.*, 2009; Vijayan and Rao, 2009). Shahbazain *et al.* (2010) isolated 15 fungal species from infected eggs of rainbow trout (*Oncorhynchus mykiss* Wallbaum) in Iran. These species included *Penicillium* spp. *Aspergillus* spp. *Alternaria* spp., *Saprolegnia* spp. and seven other species. Fadaeifard *et al.* (2011) isolated eight species of fungi; *Penicillium* spp, *Acremonium* spp, *Alternaria* spp, *Fusarium solani*, *Aspergillus* spp., *Mucor* spp., *Saprolegnia* spp. and *Cladosporium* spp. from eggs and brood stock of rainbow trout. Iqbal *et al.* (2012a) reported *Saprolegnia* sp. and *Achlya* sp. from *Catla catla* (Hamilton) and *Ctenopharyngodon idella* (Valenciennes). Das *et al.* (2012) also identified *Saprolegnia* sp. from Indian major carps. Recently, five fungal species viz. *Aspergillus* sp., *Penicillium* sp. *Alternaria* sp., *Blastomyces* sp. and *Rhizopus* sp. were isolated from four carps species, *Labeo rohita* Hamilton, *C. idella*, *Carassius auratus* L.; *Hypophthalmichthys molitrix* Richardson (Iqbal *et al.*, 2012b).

The present study was aimed and based on a hypothesis; do apparently healthy ornamental fish such as koi and shubunkin carry pathogenic fungi.

## Materials and Methods

Twenty two koi and 18 shubunkin samples were collected

from a pet fish shop in Lahore, Pakistan during August to October 2011. The fishes were shifted immediately to laboratory in sterile polyethylene bag in aerated aquarium water. The fishes were kept in glass aquaria with continuous air supply at ambient temperature. Total length (TL) and body weight (BW) of each specimen was measured and health status of every individual fish was observed.

The glassware (containing media and distilled water covered with aluminum foil), test tubes and vials (cotton plugged) were autoclaved at 121°C at 1.054 kg/cm<sup>2</sup> for 15 min. Antibiotic streptomycin sulphate 250 mg was added to each preparation of media to reduce bacterial contamination. The fish samples were disinfected from surface to prevent secondary contamination with airborne spores by dipping fish in 1% formaldehyde for 1 to 5 min. Then the sample was transferred to 70% alcohol and finally several washings were given in sterilized distilled water. The fungi were isolated from infected organs of fish with sterile needle, inoculated on Sabouraud dextrose agar (SDA) (Oxoid, UK), Malt extract agar (MEA) (Oxoid, UK), and Potato dextrose agar (PDA) (M096-India). Isolation was done in Laminar flow air cabinet to avoid contamination. The agar plates were incubated at 28-30°C and fungal growth was observed after 4-7 days. Slides were prepared by taking material from each colony and stained with 0.05% Trypanblue in lactophenol. The slides were observed under Digipro-labomed microscope and photographed. The fungi were identified with the help of available fungal identification keys and literature (Willoughby, 1994).

### Statistical Analysis

The fish body was divided into two parts; Anterior part (including head, eyes and gills) and posterior part (including all fins, abdomen and lateral sides of the fish) to note the infected site. Chi-square test was applied to compare the infection in anterior and posterior part of the body of the infected koi and shubunkin fishes.

## Results

### Isolation of Fungi from Infected Koi Fish

Twenty two koi fish were examined with mean total length and mean weight was 99 mm and 11.4 g, respectively. Fourteen out of 22 fishes were infected thus showing an infection of 63.63%. From 14 infected fishes, eleven (78.57%) fishes showed clinical signs of fungal infection such as; cotton like growth on caudal peduncle and fins, lesion on the body; tips of gills eroded. The remaining three infected fishes (Fish no. 3, 4, 12) had concurrent parasitic and fungal infection. The parasite infecting the fish was *Argulus foliaceus* L. (The parasitic infection of koi with *A. foliaceus* is discussed elsewhere). Eight fishes had no infection.

The material from three fishes with concurrent parasitic and fungal infection, and 11 infected fishes was taken and inoculated on three types of agar plates for

isolation of fungi. A total of 45 plates were inoculated and 45 fungal colonies were examined. In 14 infected koi, gills had higher infection than abdomen and caudal fin (31.11, 28.28 and 28.28%, respectively). Dorsal fin, pelvic fin and pectoral fin had < 5% infection (Fig. 1). Posterior part of the fish had high (68.89%) fungal infection that was significantly higher ( $\chi^2=3.38$ ;  $P=0.05$ ) than anterior part (31.11%). Three fungal genera viz. *Aspergillus* spp., *Mucor* sp. and *Rhizopus* sp. were isolated (Fig. 3A, B). The *Aspergillus* spp. was most prevalent and isolated from all the affected organs/tissues studied except pelvic fin and anal fin. *Aspergillus* sp. comprised 77.77% infection (Fig. 2). *Mucor* was recorded from gills, abdomen and caudal fin and formed 17.77% infection and *Rhizopus* was only (4.44%) and was isolated from gills and caudal fin. *Aspergillus* spp. and *Mucor* sp. grew well on three culture media.

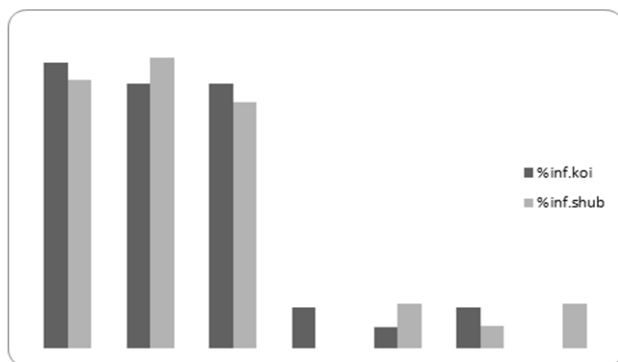
### Isolation of Fungi from Infected Shubunkin Fish

Eighteen samples of shubunkin were examined. The mean total length and weight of the fish was 84 mm and 6.11 g. Twelve fishes (66.66%) showed fungal infection with typical clinical signs; eroded skin, red patches on body, protruding eye, lesion on caudal and pelvic fins and tips of gills eroded. Six fishes had no infection and looked healthy. The material from various organs of 12 infected fishes was taken and inoculated on three types of agar plates for isolation of fungi. A total of 38 plates were inoculated and 41 fungal colonies appeared which were examined for identification. Three fungal genera, *Aspergillus* spp. *Mucor* sp. and *Rhizopus* sp. were isolated.

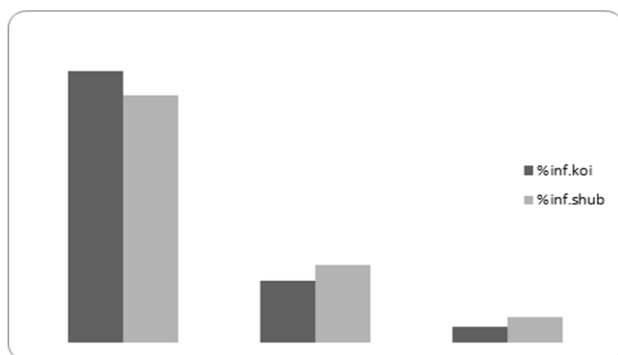
In 12 infected shubunkin, abdomen had higher infection than gills and caudal fin (31.70%, 29.26% and 26.82%, respectively). Pelvic fin and pectoral fin had 4.87% infection each and dorsal fin had very low infection (2.43%). Posterior part of the fish had high (68.29%) fungal infection that is significantly higher ( $\chi^2=3.35$ ;  $P=0.05$ ) than anterior part (31.70%). The *Aspergillus* spp. and *Mucor* sp. was isolated from all the six organs/tissues studied. *Rhizopus* sp. was only isolated from gills, abdomen and caudal fin. *Aspergillus* spp. grew very well on three culture media. Although *Mucor* sp. showed growth on all three culture media but it gave better growth on SDA and *Rhizopus* sp. only grew on PDA and SDA. *Aspergillus* spp. was most prevalent comprising 70.73% of all the fungi isolated followed by *Mucor* sp. (21.95%) and then *Rhizopus* sp. (7.31%) (Fig. 2; Fig. 4A, B; Fig. 5A, B, C and D).

## Discussion


Mycological examination of koi fish showed that it was infected with three opportunistic fungal genera, *Aspergillus* sp., *Mucor* sp and *Rhizopus* sp. The gills, abdomen and caudal fin were the most affected areas by the fungi. *Aspergillus* sp. was the prevalent fungus isolated from koi followed by *Mucor* sp. and *Rhizopus* sp. *Aspergillus* spp. and *Mucor* sp. grew well on three culture media.



**Fig. 1:** Organ-wise percentage fungal infection of Koi and shubunkin. (Abbreviations, Abd. Abdomen, CdF. Caudal fin; PvF. Pelvic fin, PcF. Pectoral fin, DF. Dorsal fin, AnF. Anal fin)

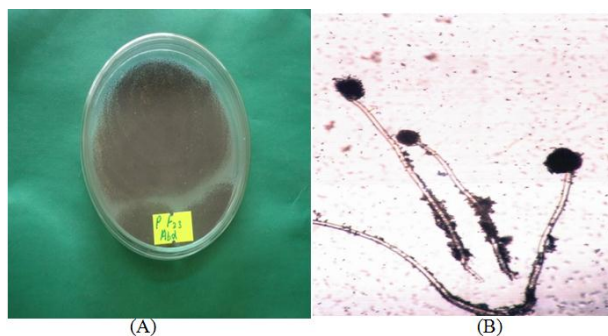


**Fig. 2:** Percentage fungal genera isolated from koi and shubunkin

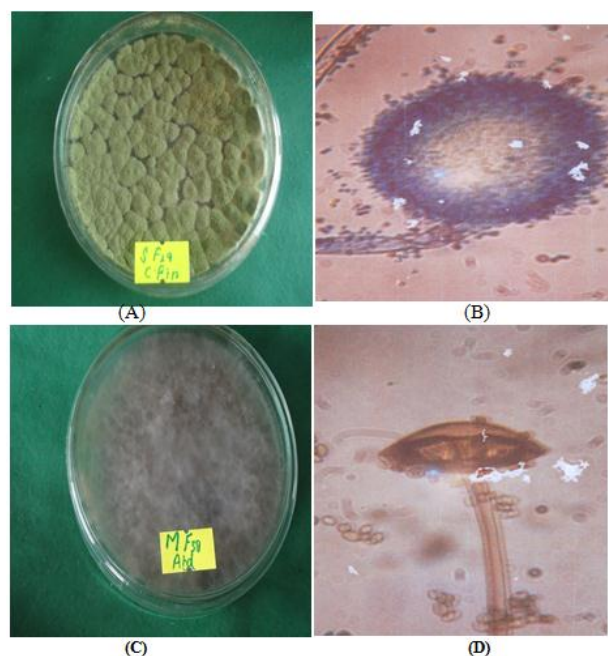


**Fig. 3:** A. Colony of *Mucor* sp. on MEA from abdomen of koi fish No.19. (B). *Mucor* sp. isolated from A

In shubunkin, gills had higher infection than rest of the organs. The *Aspergillus* spp. *Mucor* sp. was isolated from the six organs/tissues studied. *Rhizopus* sp. was isolated from gills, abdomen and caudal fin. *Aspergillus* spp. grew very well on SDA, PDA and MEA. *Mucor* sp. showed better growth on SDA and *Rhizopus* sp. only grew on PDA and SDA. Posterior part of both the fishes had significantly higher infection than anterior part.



**Fig. 4:** A. Colony of *Aspergillus* sp. on PDA from abdomen of shubunkin fish No. I (F.23). B. *Aspergillus* sp. isolated from A, three reproductive head on hyphae very clear



**Fig. 5:** A. Colony of *Aspergillus* sp. on SDA from caudal fin of shubunkin fish No.7 (F.29). (B). *Aspergillus* sp. isolated from A, with reproductive head and liberating black conidia. (C). Colony of *Rhizopus* sp. on MEA from abdomen of shubunkin fish No. 16 (F.38). (D). *Rhizopus* sp. isolated from C

Aspergillomycosis is principally a disease of tilapia (*Oreochromis* sp.) caused by *Aspergillus* spp. (Olufemi, 1985; Willoughby, 1994). These fungal species are infectious through contamination of fish feed (Saleem *et al.*, 2012). Moreover, the fungal load increase significantly during storage and is more pronounced at high moisture levels in ground and tree nuts (Jubeen *et al.*, 2012). The factors which enhance the threat of fungal infection through feeds include environmental temperature (27°C), humidity level greater than 62% and moisture level in the feed above 14%. Poor water quality is one of the most important factors

favoring the growth of fungus (Iqbal *et al.*, 2012b). *Aspergillus* sp. may have more indirect effect in tropical conditions, if poorly stored fish feed especially oil seed is held under tropical conditions and is contaminated with *Aspergillus flavus*. It is assumed that these ornamental fishes might be infected through contaminated feed offered to them at the pet shop. Fungal infections result in serious pathological conditions such as, extensive systemic infection with fungal hyphae in internal organs especially liver. However, fin infection is considered less pathogenic and serious; as such fishes survive, although fin infection may lead to complete erosion and damage of the fins (Iqbal *et al.*, 2012a). The single most affected site on fish was gills in both fishes. The infection on sensitive area like gills and eyes of fish become fatal, as the growth of fungal hyphae in eyes may cause partial or complete blindness. In such condition the treatment and cure is impossible and ultimately the fishes die (Srivastava, 2009; Iqbal, *et al.*, 2012a).

Isolation of *Aspergillus* sp., *Mucor* sp and *Rhizopus* sp. from koi and shubunkin is comparable to the findings of Refai *et al.* (2010); Shahbazain *et al.* (2010), Fadaeifard *et al.* (2011) and Iqbal *et al.* (2012b). However, Refai *et al.* (2010) has characterized *Aspergillus* spp., *Penicillium* spp. and *Rhizopus* spp. as normal mycoflora. These fungi may not be considered as non-pathogenic. But they can better understood as opportunist fungi (Refai *et al.*, 2004) as many of them possess virulence factors, which enable them to cause disease, especially under predisposing conditions (Refai *et al.*, 2010). The interaction of physiochemical factors, generally influence the diversity of water molds (Pailwal and Sati, 2009).

Poor aquarium management in the pet shops increases the chances of fungal infection in ornamental fishes. Even the basic health management practices may be easily ignored due to shortage of trained personals. This study has indicated that although fungi isolated from koi and shubunkin are considered as normal mycoflora, still they can cause infections and have roll in affecting health of ornamental fish.

## Acknowledgements

We are highly grateful to Dr. Abdul Nasir Khalid, Department of Botany, University of the Punjab, Lahore, Pakistan for confirmation and identification of fungi. This work was funded by University of the Punjab, Lahore under faculty development program.

## References

Ahilan, B., N. Felix and J.D. Jamesson, 2009. *Goldfish*. Daya Publishing House, Delhi, India

- Ahmed, N., 1996. Extraction, Exploration and demand forecasting for aquarium fishes from Pakistan. *Ph.D. Thesis*, p: 225. Department of Economics, University of Karachi, Karachi, Pakistan
- Bangyeekhun, E. and M.A. Sylvie, 2001. Characterization of *Saprolegnia* sp. Isolates From Channel Catfish. *Dis. Aquat. Organ.*, 45: 53–59
- Chukanhom, K. and K. Hatai, 2004. Freshwater Fungi Isolates from Eggs of The Common Carp (*Cyprinus carpio*) in Thailand. *Myoscience*, 45: 42–48
- Das, S.K., K. Murmu, A. Das, I. Shakuntla, R.K. Das, S.V. Ngachen and S.K. Majhi, 2012. Studies on identification and control of pathogen *Saprolegnia*, in selected Indian major carps fingerlings at mid hill altitude. *J. Environ. Biol.*, 33: 545–549
- FAO, 2007. *Fishery Statistics, Aquaculture Production*, 2005. Food and Agriculture Organization. FAO, Rome. Italy
- Fadaeifard, F., M. Raissay, H. Bahrami, E. Rahimi and A. Najafipour, 2011. Freshwater Fungi Isolated from Eggs and Broodstocks with an Emphasis on *Saprolegnia* in Rainbow Trout Farms in West Iran. *Afr. J. Microbiol.*, 4: 3647–3651
- Iqbal, Z., M. Asghar and Rubaba, 2012a. Saprolegniasis in two commercially important carps. *Pak. J. Zool.*, 44: 515–520
- Iqbal, Z., U. Sheikh and R. Mughal, 2012b. Fungal infections in some Economically important freshwater fishes. *Pak. Vet. J.*, 32: 422–426
- Jubeen, F., I.A. Bhatti, U. Maqbool and S. Mehboob, 2012. Fungal incidence, aflatoxin B1, tocopherols and fatty acids dynamics in ground and tree nuts during storage at two moisture levels. *Int. J. Agric. Biol.*, 14: 521–527
- Kwanprasert, P., C. Hangavant and N. Kitancharoen, 2007. Characteristics of *Achlya bisexualis* Isolated from Eggs of Nile Tilapia (*Oreochromis niloticus* Linn.). *KKU Res J.*, 12: 195–202
- Olufemi, B.E., 1985. The Aspergilli as pathogen of cultured fishes. In: *Recent Advances of Aquaculture*, pp: 193–218. Munir, J.F. and R.J. Roberts (eds.). Croom Helm, Calardo, USA
- Pailwal, P. and S.C. Sati, 2009. Distribution of Aquatic fungi in relation to physiochemical factors of Kosi River in Kumaun Himalaya. *Nat. Sci.*, 7: 70–74
- Refai, M., S. Attia, R.M. Salem and E.M. El-Dahsham, 2004. Studies on the pathology of *Aspergillus fumigatus*, *A. flavus* and *A. niger* isolated from chicken and their environment. *Egypt J. Comp. Path. Clinic Path.*, 17: 193–205
- Refai, M., K. Laila, A. Mohamed, M. Kenawy and El-SMS. Shamaa, 2010. The Assessment of Mycotic settlement of freshwater fishes in Egypt. *J. Amer. Sci.*, 6: 595–602
- Roberts, R.J., 2004. *Fish Pathology*, 3<sup>rd</sup> edition. Elsevier Limited, UK
- Salem, A.A., M. Refai, I.A. Eissa, M. Mmarzouk, A. Bakir, M. Mustafa and A. Mandmanal, 1989. Some studies on aspergillomycosis in Tilapia nilotica. *Zagazig Vet. J.*, 17: 315–328
- Saleem, M.J., A. Hanan, A.U. Nisa and T.A. Qasir, 2012. Occurrence of Aflatoxins in Maize seed under different conditions. *Int. J. Agric. Biol.*, 14: 473–476
- Shahbazain, N., M. Ebrahimzadeh, M. Soltani, A.R. Khosravi, S. Mirzagai and I. Sharifpour, 2010. Fungal contamination in rainbow trout eggs in kermanshah province propagation with emphasis on Saprolegniaceae. *Iran. J. Fish Sci.*, 9: 151–160
- Siddique, M.M.R., M.A. Basher, M.A. Hussain and A.S.M. Kibria, 2009. Fungal disease of freshwater fishes in natore district of Bangladesh. *J. Bang. Agric. Uni.*, 7: 157–162
- Srivastava, R.C., 2009. *Fish Mycopathology*. Today and Tomorrow's Publishers New Dehli, India
- Vijayan, K.K. and G.S. Rao, 2009. *Animals Including Fishes and their Pest*. In: *Invasive Alien Species, A threat to Biodiversity*. ICAR, MEF. Govt. of India, New Dehli, India
- Willoughby, L.G., 1994. *Fungi and Fish Diseases*. Pisces Press, Stirling, UK

(Received 01 August 2012; Accepted 11 January 2013)