



Full Length Article

Expression of Genes Encoding TFF3 in Intestinal Tissues during Weaning in Diarrhea Piglets Induced by Enterotoxigenic *Escherichia coli*

Hui Zhang^{1†}, Zhenyu Chang^{1†}, Mujeeb Ur Rehman¹, Khalid Mehmood^{1,2}, Rong Deng¹, Xiaoxing Wu¹, Fazul Nabi^{1,3}, Xinxin Tian¹, Xiaodan Yuan¹ and Donghai Zhou^{1*}

¹College of Veterinary Medicine, Huazhong Agricultural University, Wuhan 430070, People's Republic of China

²University College of Veterinary and Animal Sciences, The Islamia University of Bahawalpur, 63100, Pakistan

³Lasbela University of Agriculture, Water and Marine Science, Uthal, Pakistan

*For correspondence: bigdefoot@163.com; 1782492444@qq.com

†These authors made equal contributions to this article

Abstract

TFF3 (Trefoil factor family 3) is a mature peptide composed of 59 AAs, known to be expressed in intestinal epithelial cells of various organisms and are often co-secreted with mucins by mucus-producing cells. The expression of TFF3 in tissue changed the specificity in disease condition. The aim of this study was to determine the expression of TFF3 gene in diarrhea weaning piglets induced by enterotoxigenic *Escherichia coli*. For this purpose, a total of 24 Duroc piglets were divided into two groups: diarrhea groups (n=12) infected with Enterotoxigenous *E. coli* and control groups (n=12) with a standard normal diet. Immunohistochemistry was performed to observe the expression of TFF3 protein in intestinal tissues of piglets. Expressions of genes encoding TFF3 were increased in the intestinal tissues of diarrhea piglets as compare with the control piglets. Moreover, the greater staining of TFF3 was detected on the 1st (P<0.01) and 3rd (P<0.05) days in the duodenum of the diarrhea groups, and 3rd days in the jejunum (P<0.01); in contrast, 3rd and 5th days in the ileum, cecum and colon. These findings indicate that the TFF3 gene play a role in all of the intestinal tissues along with the periods of diarrhea, especially in jejunum and ileum of weaning piglets. © 2017 Friends Science Publishers

Keywords: TFF3; Immunohistochemistry; Weaning piglets; Diarrhea; Intestinal tissues

Introduction

Weaning is recognized as one of the highly lethal infectious disease in commercial swine production (Pei *et al.*, 2010; Luppi *et al.*, 2016; Yue *et al.*, 2016). During this period, the newly weaned pig encounters psychosocial and physical stressors which can initiate the Early-weaning syndrome (Moeser *et al.*, 2007). Most weaned piglets show non-infectious diarrhea symptoms such as increased excretion of fatty acids and carbohydrates in the feces and degenerative change in villi of the small intestine (Kyriakis, 1989). In some cases, opportunistic pathogens, particularly *Escherichia coli* take advantage of the presence of this diarrhoea and cause the syndrome in post weaning diarrhoea (Kyriakis, 1989). Diarrhea is not only an important cause of death in pigs, but also one of the most difficult conditions. Because the etiology of diarrhea is different, complex condition, high incidence, partially cure which leads to slow growth of piglets or becoming "deadlock pigs" which can cause feeding reward to reduce and cost to increase and other consequences (Jiang *et al.*, 2009). It has brought huge economic loss to the pig industry. TFF3 is known to be expressed in intestinal epithelial cells of various organisms

and often co-secretes with mucins by mucus-producing cells. TFF3 is secreted as a monomer or dimer and provide protective and reparative effects by enhancing epithelial integrity and promoting mucosal restoration. The specific expression of TFF3 in tissues can be changed in disease condition. Mucosal damage can induce the expression of TFF3. This study was designed to discuss the expression of TFF3 in intestinal track of piglets which were established in the model with Enterotoxigenic *E. coli*. The purpose of this study was to identify the relationship between the TFF3 and intestinal mucous barrier by analyzing the expression of TFF3 protein in the presence of diarrhea at various days in weaning piglets.

Materials and Methods

Reagents and Materials

Rabbit anti-TFF3 antibody, anti-rabbit horseradish secondary antibody and DAB were purchased from commercial company (Wuhan, China). ETEC K88O₁₄₉ strain was given by the Institute of Veterinary Drugs Control, China. L-polylysine was obtained from Sigma-Aldrich.

Inverted microscope was purchased from Olympus Company. Microwave oven was purchased from Galanz Company. Disposable blades were purchased from LEICA Company, and precision acidity meter was purchased from Thermo Orion Company.

Ethics Approval

All the experiments were conducted according to the institutional Animal Welfare and Research, Ethics Committee guideline of Huazhong Agricultural University Wuhan, China.

Animals and Treatment

A total of 24 Duroc piglets (25–28 days and weighing ~7 kg) were provided by Hubei Academy of Agricultural Sciences, China. The piglets were randomly divided into two equal groups. The control group (n=12) administered with a standard normal diet; the diarrhea groups (n=12) infected with pathogenic *E. coli*. A total of 4 healthy piglets and 4 diarrheal piglets were sacrificed according to the guidelines for the care approved by the committee of Huazhong Agricultural University on the 1st, 3rd and 5th day, respectively. Sodium pentobarbital was used to anaesthetize the piglets prior to open the gut and dissect the intestinal tissues. The sections were cleaned 3 times in 0.9% NaCl cold solution and fixed in 10% neutral-buffered formalin by immersion. Fixed pieces were washed with 70% (v/v) ethanol, then dehydrated and embedded in paraffin, and stored at 4°C for future use.

Immunohistochemistry of TFF3 in the Piglet Intestinal Tract

Paraffin sections of approximately 4 µm were cut and mounted on silane coated slides. The slides were heated for 45 min at 58°C. Subsequently, the sections were deparaffinized in xylene, rehydrated through graded ethanol and rinsed in distilled water and PBS (pH 7.4). To block the endogenous peroxidase activity the sections were incubated once with 3% (v/v) hydrogen peroxide in methanol for 15 min at room temperature, and rinsed 3x with PBS (pH 7.4). Unspecific binding was blocked by dipping in 5% solution of normal Bovine Serum Albumin for 30 min at 37°C. Sections were then incubated overnight at 4°C with the primary TFF3 antibody diluted 1:160 in PBS (pH 7.4). Control sections were processed simultaneously with PBS instead of the primary antibody. After 3 times wash, the biotinylated goat anti-rabbit linking antibody (1:200) was used to flood the slides for 20 min at 37°C. Sections were again washed in PBS two times, treated with peroxidase-conjugated avidin for 30 min, rewashed twice in PBS. Diaminobenzidine (DAB plus, 5 min, under visual control) was taken as chromogen and hemalum as counterstain. Mayer's hematoxylin counterstain was used to stain gut sections for 1 min, and then de watered and mounted by

neutral balsam to analyze under a microscope (Olympus, Japan). Alongside the primary antibodies were removed in negative control.

Statistical Analysis

The collected data was analyzed with one way ANOVA by using student t-test to compare the differences between mean values of control and diarrhea groups. The differences were considered statistically significant if $P < 0.05$. Values are presented as means \pm standard error of means (S.E.M). All statistical analysis was performed by using SPSS 19.0 software.

Results

The Clinical Symptoms of Diarrhea in Piglets

The diarrhea group of 12 piglets showed varying degrees of diarrhea manifested as cachexia, anorexia, and some already dry stool around the anus after the oral ingestion of *E. coli* about 24 h. As the extension of time, diarrhea symptoms were aggravated and the emergence of vomiting symptoms in individual piglets. We can see different degrees of hemorrhage in gastrointestinal mucosa, thinning of intestinal wall, stench of intestinal contents, bubbles of individual piglets when the piglets were dissected.

Immunolocalization of TFF3 in the Piglet Intestinal Tract

It was found that TFF3 protein was expressed throughout the intestinal tract, including the duodenum, jejunum, ileum, cecum and colon (Figs. 1–5), and most of TFF3 existed in the mucosa of intestinal tract. Image-Pro Plus software was used to calculated TFF3 positive areas in pictures of immunohistochemistry and the results of TFF3 expression were recorded by the mean density of the positive cells (Table 1).

Immunohistochemical Localization of TFF3 Protein in the Duodenum of Piglets

TFF3 protein was found expressed in the duodenum of the control group and diarrhea group. Integrate intestinal mucosa existed and the positive area were mainly distributed clearly in the intestinal mucosa in the control group. The structure of intestinal mucosa was not liearly, and larger positive region which were observed in mucosa and submucosa.

Immunohistochemical Localization of TFF3 Protein in the Jejunum of Piglets

TFF3 protein was found expressed in the mucosa of jejunum both in the control group and diarrhea group. There were greater staining and fracture, loss and other damage phenomenon in the diarrhea group.

Table1: Expression of TFF3 protein in different organs

Organs	Groups	1d	3d	5d
Duodenum	Control	0.0878±0.0273 ^{Aa}	0.1811±0.0119 ^{Ab}	0.1611±0.0170 ^{Ab}
	Diarrhea	0.1589±0.0133 ^{Ba}	0.2472±0.0313 ^{Bb}	0.1756±0.0078 ^{Aa}
Jejunum	Control	0.1436±0.0191 ^{Aa}	0.1588±0.0061 ^{Aa}	0.1808±0.0119 ^{Ab}
	Diarrhea	0.1899±0.0253 ^{Aa}	0.2301±0.0258 ^{Bb}	0.2005±0.0214 ^{Bab}
Ileum	Control	0.1436±0.0191 ^{Aa}	0.1588±0.0061 ^{Aa}	0.1808±0.0119 ^{Ab}
	Diarrhea	0.1899±0.0253 ^{Aa}	0.2301±0.0258 ^{Bb}	0.2005±0.0214 ^{Bab}
Cecum	Control	0.1061±0.0136 ^{Aa}	0.1216±0.0152 ^{Ab}	0.1214±0.0078 ^{Ab}
	Diarrhea	0.1335±0.0191 ^{Aa}	0.2285±0.0146 ^{Bb}	0.2025±0.0156 ^{Bb}
Colon	Control	0.1320±0.0263 ^{Aa}	0.1757±0.0988 ^{Ab}	0.1575±0.0153 ^{Aab}
	Diarrhea	0.1161±0.0107 ^{Aa}	0.2755±0.0494 ^{Bb}	0.1834±0.0065 ^{Bc}

Note: a, b means lacking common superscripts within a row are significantly different at $P < 0.05$. A, B means lacking common superscripts within a column are significantly different at $P < 0.05$

Immunohistochemical Localization of TFF3 Protein in the Ileum of Piglets

The positive reaction of TFF3 was found in the control group and diarrhea group. Positive areas were mainly distributed in the mucous layer, and a small amount was distributed in the submucosa in the control group. Apparent positive reaction was found in the goblet cells and around the mucous layer in the diarrhea group.

Immunohistochemical Localization of TFF3 Protein in the Cecum of Piglets

The positive area was found in cecum. The positive reaction was weak, mainly to the mucous surface in the control group. Further observations revealed elevating staining of TFF3 within the mucosa, greater staining in the goblet cell area and larger, darker staining in the diarrhea group as compared to control group.

Immunohistochemical Localization of TFF3 Protein in the Colon of Piglets

The positive reaction of TFF3 was found in the colon, and mainly distributed in the goblet cells and mucous layer. There was a weak reaction both in the control group and the diarrhea group.

Expression of TFF3 Protein in the Duodenum

The expression quantity in duodenum was increased first and then decreased slightly with the period of piglet diarrhea. There was a higher expression quantity of TFF3 in the diarrhea group compared with control group, and signification on the first day ($P < 0.01$) and third day ($P < 0.05$). The lowest expression of volume of TFF3 in duodenum was found on the first day in the control group, and much lower than the third day and fifth day ($P < 0.05$). The highest expression of volume of TFF3 in duodenum was found on the third day in the diarrhea group, and it was much higher than the first day ($P < 0.01$) and fifth day ($P < 0.05$) as given in Table 1.

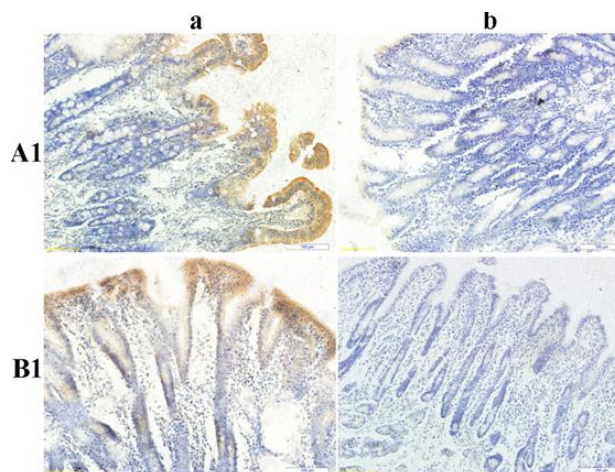


Fig. 1: Immunohistochemical localization of TFF3 protein in the duodenum of piglets. A1) control group; B1) diarrhea group; Right pictures: negative controls; chromogen: DAB (brown), scale bars represent 100 μm

Expression of TFF3 Protein in Jejunum

A progressive increase in TFF3 protein was observed in jejunum with the periods of diarrhea in piglets (Table 1). There was a higher expression quantity of TFF3 in the diarrhea group compared with control group, especially on the third day ($P < 0.01$). Highest mean expression values were found on the fifth day in the control group, and much higher than the first day and third day ($P < 0.01$). Lowest mean expression values were found on the first day in the diarrhea group, and much lower than the third day ($P < 0.01$) and fifth day ($P < 0.05$).

Expression of TFF3 Protein in Ileum

The expression tendency in ileum looks like that in the jejunum of control group, but the expression quantity in diarrhea group increased first and then decreased slightly (Table 1). There was a higher expression quantity of TFF3 on the third day and fifth day compared with control group ($P < 0.01$). Highest mean expression values were found on

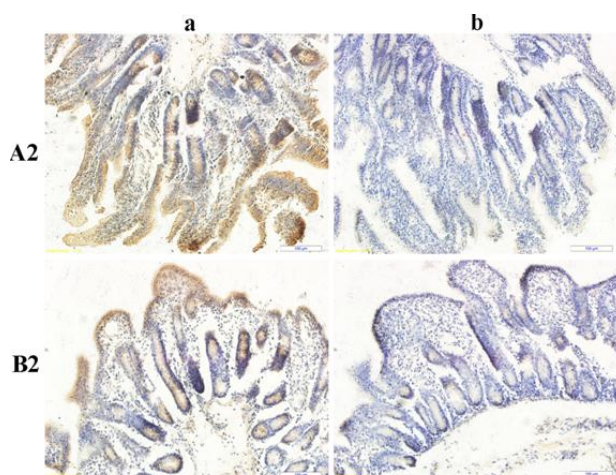


Fig. 2: Immunohistochemical localization of TFF3 protein in the jejunum of piglets. A2) control group; B2) diarrhea group; Right pictures: negative controls; chromogen: DAB (brown), scale bars represent 100 μ m

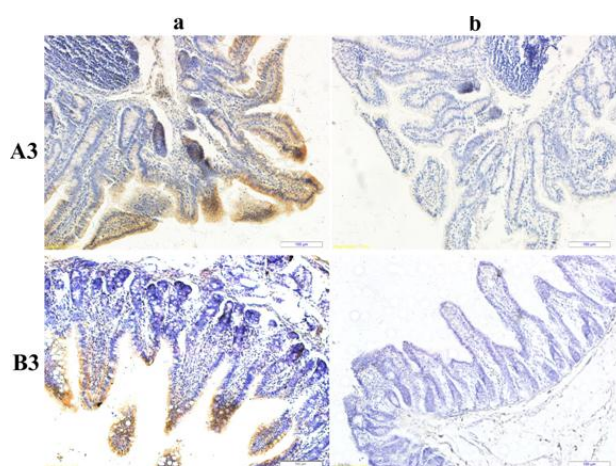


Fig. 3: Immunohistochemical localization of TFF3 protein in the ileum of piglets. A3) control group; B3) diarrhea group; Right pictures: negative controls; chromogen: DAB (brown), scale bars represent 100 μ m

the fifth day in the control group, and much higher than the first day and the third day ($P<0.01$). Lowest mean expression values were found on the first day in the diarrhea group, and much lower than the third day ($P<0.01$).

Expression of TFF3 Protein in Cecum

The expression quantity in cecum was increased first and then decreased slightly with the periods of diarrhea in piglets. There was a higher expression quantity of TFF3 in the diarrhea group compared with control group, and signification on the third and fifth day ($P<0.01$). The lowest expression of volume of TFF3 in cecum was found on the first day both in the control group and diarrhea group, and

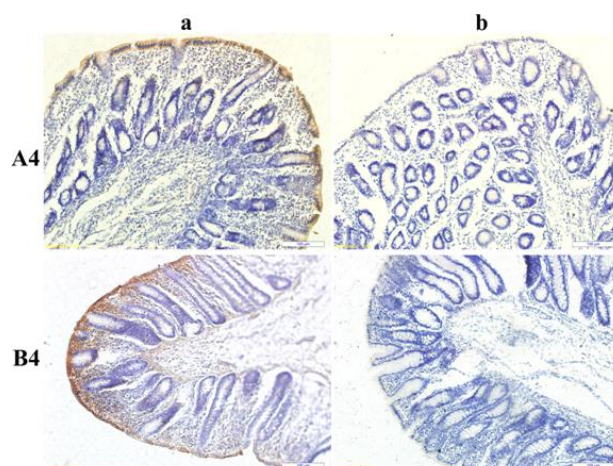


Fig. 4: Immunohistochemical localization of TFF3 protein in the cecum of piglets. A4) control group; B4) diarrhea group; Right pictures: negative controls; chromogen: DAB (brown), scale bars represent 100 μ m

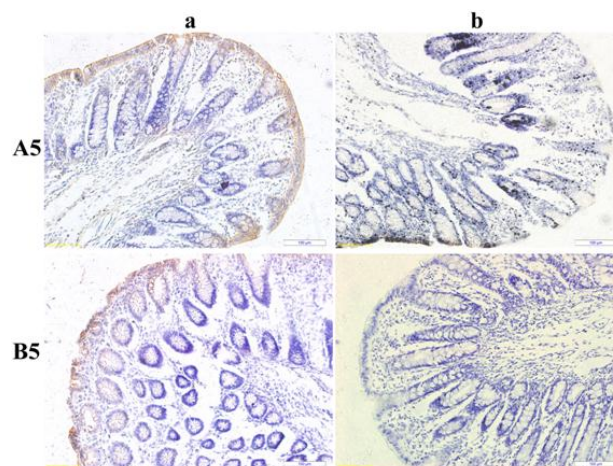


Fig. 5: Immunohistochemical localization of TFF3 protein in the colon of piglets. A5) control group; B5) diarrhea group; Right pictures: negative controls; chromogen: DAB (brown), scale bars represent 100 μ m

much lower than the third day and fifth day ($P<0.01$) which proved that the serious damage was existed in third day and fifth day (Table 1).

Expression of TFF3 Protein in Colon

A higher expression quantity of TFF3 on the third day and fifth day of the diarrhea group compared with control group ($P<0.01$). Lower mean expression values were found on the first day, and much lower than the third day and fifth day ($P<0.01$) in control group. The lowest expression quantity in diarrhea group was on the first day too, and different significant between the first day, third day and fifth day ($P<0.01$).

Discussion

Piglets are faced with many new challenges during the post weaning period such as a change in diet, removal from the sow and other littermates and a new environment (Cabrera *et al.*, 2010; Smith *et al.*, 2010). These stressors can lead to an intestinal imbalance between beneficial and non-beneficial microflora, which is associated with the growth of harmful microbes such as *E. coli*, rotavirus, *Clostridium perfringens* which could induce the weaning diarrhea syndrome (Juul-Madsen *et al.*, 2010).

Post-weaning diarrhea often affects piglets in the first weeks after weaning (Orgeur *et al.*, 2001). The basic pathogen characteristics incorporated into the model (the fact that the pathogen attaches to the intestinal wall) are namely common to several pathogens that infect the gastrointestinal tract (Orgeur *et al.*, 2001; Salmon *et al.*, 2009). Post-weaning diarrhea can follow an infection in newly weaned piglets by enterotoxigenic *E. Coli* that expresses F4 fimbriae (F4+*E. coli*). F4+*E. coli* can attach to the microvilli of the small intestine enterocytes, where they produce enterotoxins. These toxins affect the enterocytes and cause increase in secretion of fluid which lead to diarrhea, dehydration, acidosis, or in some cases, even to death (Geenen *et al.*, 2007). Previously, several empirical studies have investigated how the occurrence of clinical symptoms depends on environmental factors, such as weaning age, diet composition, temperature and litter size (Callesen *et al.*, 2007). Furthermore, recently some field studies report data on shedding patterns of infected piglets and provide estimates of transmission parameters. A progressive increase of endotoxin, TNF- α , IL-6 and DAO in plasma with the periods of diarrhea in piglets which were infected by ETEC compared with the control groups. It proved that there were injuries in the gastrointestinal mucosa tissue of piglets during the period of diarrhea (Pei *et al.*, 2010).

TFF3 provide protective and reparative effects by enhancing epithelial integrity and promoting mucosal restitution. The expression of TFF3 is induced after mucosal damage. These processes are of central physiological relevance during the postnatal intestinal development and are strongly influenced during the weaning period. In piglets, weaning at early maturation stages frequently causes mucosal inflammation (Scholven *et al.*, 2009). Postnatal intestinal development is a complex process resulting in essential morphological and functional changes of the mucosa. These alterations are controlled by intrinsic programming, endogenous hormones and extrinsic luminal factors. The weaning phase is one of the important developmental period characterized by massive exposure to novel antigens and enhancing the modifications of the small intestine. Epithelial cells lining the gastrointestinal mucosa are composed of distinct cell types, each of which contributes in a unique way to mucosal defense and the maintenance of barrier integrity. Restoration of epithelial continuity following injury or environmental challenges

requires a regulatory network controlling diverse mechanisms of epithelial repair like gene expression, cell migration, proliferation and reestablishment of cell-cell contacts (Mammen and Matthews, 2003). TFF3 is known to be expressed in intestinal epithelial cells of various organisms and often co-secreted with mucins by mucus-producing cells. Recent studies have uncovered a role of TFF3 in maintaining intestinal epithelial integrity based on restitution, wound healing, apoptosis, cell motility and adhesion (Durer *et al.*, 2007). In modulating mucosal immune responses at the level of leukocyte recruitment and tissue repair functions (Soriano-Izquierdo *et al.*, 2004). TFF3 has a major impact on maintenance of healthy mucosal surfaces. It is regulated by both pro-inflammatory and anti-inflammatory cytokines. One of the important local cytokines like regulating TFF2 and TFF3 during mucosal repair is the transforming growth factor- α (TGFA) (Baus-Loncar and Giraud, 2005). TGFA is thought to be the main endogenous epidermal growth factor receptor (EGFR) ligand in the intestine controlling cell proliferation and cell migration of gastrointestinal epithelial cells (Hormi and Lehy, 1996). Like EGF, TFF3 is able to actively support epithelial repair through their mutagenic activity. In addition, pathways of TFF2 and TFF3 have been indirectly connected to EGFR through cyclooxygenase 2 (Cox-2) dependent signaling affecting *in vitro* proinvasive properties (Rodrigues *et al.*, 2003). In human, TFF3 is mainly expressed in goblet cells of the small intestine and colon, and in Brunner's glands of the small intestine. An up regulated expression of TFF3 around the weaning period was measured in rat intestine (Lin *et al.*, 1999).

The expression of TFF3 protein was found in the intestinal tissues and mainly observed in the intestinal mucous in the present study. This underlines a possible role of TFF3 in the response to diarrhea associated injuries in mucous membrane in post-weaning piglets. A progressive increase in TFF3 protein was observed in the diarrhea group and control group with the periods of diarrhea in piglets, especially in jejunum and ileum, which concordant with Scholven's results (Scholven *et al.*, 2009). In summary, it has been demonstrated that TFF3 expression is differently regulated during the diarrhea period in early weaning piglets and much higher than the control piglets. The main reason might be due to the effect of TFF3, which could prevent and repair the injury of mucous membrane in the diarrhea program. However, our lack of understanding the process of participates in the intestinal mucosa injury repair and regulatory steps in TFF3 biology. Study of the regulation is important for mucosal protection, disease treatment and diagnosis and treatment of tumor and some other aspects.

Acknowledgment

This study was supported by Hubei Provincial Natural

Science Foundation of China (Grant No: 2014CFB244), Supported by the Fundamental Research Funds for the Central Universities (Program No: 2011PYO78).

References

- Baus-Loncar, M. and A.S. Giraud, 2005. Multiple regulatory pathways for trefoil factor (TFF) genes. *Cell Mol. Life Sci.*, 62: 2921–2931
- Cabrera, R.A., R.D. Boyd, S.B. Jungst, E.R. Wilson, M.E. Johnston, J.L. Vignes and J. Odle, 2010. Impact of lactation length and piglet weaning weight on long-term growth and viability of the progeny. *J. Anim. Sci.*, 88: 2265–2276
- Callesen, J., D. Halas, F. Thorup, K.B. Knudsen, J.C. Kim, B.P. Mullan, D.J. Hampson, R.H. Wilson and J.R. Pluske, 2007. The effects of weaning age diet composition and categorisation of creep feed intake by piglets on diarrhoea and performance after weaning. *Livest. Sci.*, 108: 120–123
- Durer, U., R. Hartig, S. Bang, L. Thim and W. Hoffmann, 2007. TFF3 and EGF induce different migration patterns of intestinal epithelial cells *in vitro* and trigger increased internalization of E-cadherin. *Cell Physiol. Biochem.*, 20: 329–346
- Geenen, P.L., J. Van der Meulen, A. Bouma, B. Engel, J.A.P. Heesterbeek and M.C.M. De Jong, 2007. Classification of temporal profiles of F4+ E. Coli shedding and faecal dry matter in experimental post-weaning diarrhoea of pigs. *Epidemiol. Infect.*, 135: 1001–1009
- Hormi, K. and T. Lehy, 1996. Transforming growth factor- α *in vivo* stimulates epithelial cell proliferation in digestive tissues of suckling rats. *Gut*, 39: 532–538
- Scholven, J., D. Taras, S. Sharbati, J. Schon, C. Gabler, O. Huber, D.M. Zum Buschenfelde, N. Blin and R. Einspanier, 2009. Intestinal Expression of TFF and Related Genes during Postnatal Development in a Piglet Probiotic Trial. *Cell Physiol. Biochem.*, 23: 143–156
- Jiang, X., D. Wang, X. Zhao, X. Qi, H. Liu and J. Huang, 2009. The research of probiotics xylooligosaccharide effect on flavo-white diarrhea precaution and growth performance of piglets. *Acta Agric. Bor. Occident. Sin.*, 18: 59–62
- Juul-Madsen, H.R., K.H. Jensen, J. Nielsen and B.M. Damgaard, 2010. Ontogeny and characterization of blood leukocyte subsets and serum proteins in piglets before and after weaning. *Vet. Immunol. Immunopathol.*, 133: 95–108
- Kyriakis, S.C., 1989. New aspects of the prevention and/or treatment of the major stress induced diseases of the early weaned piglet. *Pig News Inform.*, 2: 177–181
- Lin, J., I.R. Holzman, P. Jiang and M.W. Babyatsky, 1999. Expression of intestinal trefoil factor in developing rat intestine. *Neonatology*, 76: 92–97
- Luppi, A., M. Gibellini, T. Gin, F. Vangroenweghe, V. Vandenbroucke, R. Bauerfeind, P. Bonilauri, G. Labarque and Á. Hidalgo, 2016. Prevalence of virulence factors in enterotoxigenic *Escherichia coli*, isolated from pigs with post-weaning diarrhoea in Europe. *Porcine Health Manage.*, 2: 20–26
- Mammen, J.M. and J.B. Matthews, 2003. Mucosal repair in the gastrointestinal tract. *Crit. Care Med.*, 31: 532–537
- Moeser, A.J., C.V. Klok, K.A. Ryan, J.G. Wooten, D. Little, V.L. Cook and A.T. Blikslager, 2007. Stress signaling pathways activated by weaning mediate intestinal dysfunction in the pig. *Amer. J. Physiol. Gastroint. Liver Physiol.*, 292: 173–181
- Orgeur, P., M. Hay, P. Mormède, H. Salmon, J. Le Dividich, R. Nowak, B. Schaal and F. Levy, 2001. Behavioural, growth and immune consequences of early weaning in one week old large white piglets. *Reprod. Nutr. Dev.*, 41: 321–332
- Pei, X.Y., D.Z. Guo, D.H. Zhou, R. Guo, H.M. Gao and T. Xia, 2010. Protease-activated receptor-2 (PAR-2) regulates enterotoxigenic *Escherichia coli*-induced diarrhea during weaning in piglets. *Afr. J. Agric. Res.*, 5: 1439–1447
- Rodrigues, S., S. Attoub and Q.D. Nguyen, E. Bruyneel, C.M. Rodrigue, B.R. Westley, F.E. May, L. Thim, M. Mareel, S. Emami, and C. Gespach, 2003. Selective abrogation of the proinvasive activity of the trefoil peptides pS2 and spasmodic polypeptide by disruption of the EGF receptor signaling pathways in kidney and colonic cancer cells. *Oncogene*, 22: 4488–4497
- Salmon, H., M. Berri, V. Gerdt and F. Meurens, 2009. Humoral and cellular factors of maternal immunity in swine. *Dev. Comp. Immunol.*, 33: 384–393
- Smith, F., J.E. Clark, B.L. Overman, C.C. Tozel, J.H. Huang, J.E. Rivier, A.T. Blikslager and A.J. Moeser, 2010. Early weaning stress impairs development of mucosal barrier function in the porcine intestine. *Amer. J. Physiol. Gastroint. Liver Physiol.*, 298: 352–363
- Soriano-Izquierdo, A., M. Gironella, A. Massaguer, F.E. May, A. Salas, M. Sans, R. Poulosom, L. Thim, J.M. Pique and J. Panes, 2004. Trefoil peptide TFF2 treatment reduces VCAM-1 expression and leukocyte recruitment in experimental intestinal inflammation. *J. Leukoc. Biol.*, 75: 214–223
- Yue, J., C.Q. Lu, H.Y. Lin, X.N. Wang, J.Q. Zheng, J.J. Chen, and R. Gooneratne, 2016. Effect of ultrafine pulverization of senecio scandens on growth, immune system and faecal microorganisms in piglets. *Pak. Vet. J.*, 36: 425–430

(Received 11 November 2016; Accepted 24 January 2017)