



**Full Length Article**

## Lymphoid Leukosis in Fayoumi Birds Reared in Countryside

Ahrar Khan<sup>1,2\*</sup>, Fazal Mahmood<sup>1</sup>, Riaz Hussain<sup>3</sup>, Abu Bakar Siddique<sup>4</sup>, S.T. Gul<sup>1</sup>, M. Kashif Saleemi<sup>1</sup>, Fang Li<sup>2</sup> and Meiyen Shen<sup>2\*</sup>

<sup>1</sup>Department of Pathology, Faculty of Veterinary Science, University of Agriculture, Faisalabad-38040, Pakistan

<sup>2</sup>Shandong Vocational Animal Science and Veterinary College, Weifang 261061, China

<sup>3</sup>University College of Veterinary and Animal Sciences, The Islamia University of Bahawalpur- 63100, Pakistan

<sup>4</sup>Department of Microbiology, Faculty of Life Sciences, Government College University, Faisalabad, Pakistan

\*For correspondence: myshen0204@163.com; ahrar1122@yahoo.com

### Abstract

Avian leukosis, an economically important viral disease of laying type birds is not only prevalent in Pakistan but also in other countries. The present study was aimed at describing morbidity, mortality, hatchability and egg production and pathology in naturally occurring cases of avian leukosis in Fayoumi commercial layers in Punjab, Pakistan. The morbidity, mortality, hatchability and egg production were 37.75%, 5.38%, 62.25% and 68.6%, respectively. Clinical signs including emaciation, pale and anemic combs, prominent keel bones, and whitish sclera in affected birds were frequently observed. Postmortem examination revealed extensively enlarged liver that occupied the entire abdominal cavity. From small to large multiple whitish nodular necropsied areas were present on dorsal and ventral surfaces of the liver. Spleen was enlarged with marbling appearance. Bursae were significantly enlarged and significantly enlarged well differentiated multiple whitish nodules were observed cranial to ovarian clutch. Such whitish nodules were also present on intestinal and uterine tube serosal surfaces. Microscopically, entire parenchyma of liver was massively replaced by neoplastic cells. A few healthy hepatocytes were left those were also surrounded by neoplastic cells. Similar cell population was also infiltrating the splenic parenchyma, intestines and uterine tube. The PCR confirmed avian leukosis virus by amplification of specific and conserved fragment gene of 545 bp. The results of present study confirmed the presence of lymphoid leukosis in Fayoumi egg-type birds which is first time reported from Pakistan. © 2019 Friends Science Publishers

**Keywords:** Lymphoid leukosis; Fayoumi; Egg-type birds; Pathology

### Introduction

The economy of Pakistan is agro-livestock based and this sector is playing a pivotal role in rural socio-economic development (Farooqi *et al.*, 2017; Shah *et al.*, 2017). This sector is a source of income for the rural people, thus playing a key role in poverty alleviation (Khan *et al.*, 2017). Livestock sector is contributing to the agriculture value added approximately 58.6% and 11.6% to the overall GDP in Pakistan (Sohaib and Jamil, 2017). Among livestock sector poultry industry has its own importance.

Among poultry breeds, Fayoumi breed is tough, compatible to hot climate and very good foragers and layers. Usually matures fast and starts laying by 18-20 weeks while cockerels start crowing 6-8 weeks (Padhi, 2016). Due to these features, this breed is more popular in rural areas of Pakistan. This breed is thought to be resistant to most of the infections, especially viral and bacterial infections, however, some of the viral infections like avian leukosis do infect this breed and hamper its production and performance.

Myeloid leukosis caused by a retrovirus (Avian Leukosis/Sarcoma Group of Retroviruses) is

characterized by considerable losses in poultry production throughout the world. In subgroup J viral strains, diversity has been documented from various parts of the world such as North America, Europe and South East Asian countries. Avian leukosis due to J sub type virus has been reported in commercial laying flocks and local chicken breeds in African, Asian, and South East Asian countries including Egypt (Kilany *et al.*, 2015), China (Xu *et al.*, 2004; Chen *et al.*, 2005), Turkey (Venugopal *et al.*, 2000), Taiwan (Wang and Juan, 2002), India (Gopal *et al.*, 2012; Swathi *et al.*, 2012; Sagarika *et al.*, 2017) and Malaysia (Thapa *et al.*, 2004).

Leukosis infects a wide range of birds including captive wild and turkey birds (Dong *et al.*, 2015; Reinišová *et al.*, 2016). Published literature indicated severe economic losses due to ALV-J infection in layer chickens (Gingerich *et al.*, 2002; Xu *et al.*, 2004). The pathological lesions associated with avian leukosis such as whitish nodules, particularly at the visceral organs, serosal surfaces of intestinal coils and uterine tube have been reported in different avian species. These nodules are predominantly consisting of myelocytes/myeloblastic cells with characteristic

eosinophilic cytoplasmic granules (Fadly and Smith, 1999; Fadly, 2000; Witter *et al.*, 2005). However, different other lesions including histiocytic sarcomatosis and myelocyte infiltration in periosteum and bones in layers are already documented (Arshad *et al.*, 1997; Landman *et al.*, 2002).

Currently, antigenic and genomic sequencing and several advanced sensitive molecular techniques have been used for the identification of the virus. Among them, the PCR has been reported as specific, rapid and sensitive (Smith *et al.*, 1998) for the diagnosis of avian oncogenic viruses (Gopal *et al.*, 2012). Histopathological examination and serological tests are also valuable tools for the diagnosis of ALV-J infection in the morbid tissue and blood samples from affected flocks (Fadly, 2000). The status of ALV-J in Fayoumi egg-type chickens in Pakistan is not known and no reports are available for the presence and confirmation of avian leukosis virus. Therefore, this is the first pathological study of diffused and nodular forms of lymphoid leukosis in Fayoumi laying birds in Pakistan.

## Materials and Methods

### Study Area and Environment

Faisalabad is third populous city in Pakistan. It is situated at latitude 31°–26' N, longitude 73°–06' E and altitude 184.4 m. It has long summer episode that extends from May to September. In summer, ambient temperature ranges from 30 to 45°C and even sometimes may go to 48°C. A severe hot and humid (humidity 45.38±13.11%) period begins from mid July and extended up to mid-September (Khan *et al.*, 2013). Toba Tek Singh was part of district Faisalabad, due to administration reasons, it was made a new district. It has nearly similar weather conditions.

### Flocks Management and History

In present study, three commercial layer farms of Fayoumi of 10 months age present at two farms in rural areas of District Toba Tek Singh and one from district Faisalabad comprising of 6000, 11000 and 3000 birds, respectively were included. The birds were offered commercial feed mixed with vitamins. Birds were kept in open houses with curtains, as per need, curtains were dropped or raised. There was complaint that these farms have low egg production and hatchability, *i.e.*, 65% and 60-70%, respectively. The mortality was also observed. Various clinical signs such as ruffled feathers, lethargy, emaciation, somnolence, leg weakness and depression were observed in birds. Anemia, pale combs and prominent keel bone were frequently observed in layers. Previously, due presence of ticks and enlarged spleen, the birds were treated for spirochetosis. The birds were given procaine penicillin, ivomec and multivitamins. Birds were also treated with chloramphenicol and nitrofurantoin. With this treatment no improvement was observed. All the flocks with the history mentioned above were investigated by

conducting the necropsy. The impression smears prepared from peripheral blood and spleen, stained with Geimsa stained, did not show any evidence of spirochetes.

### Necropsy

Twenty birds from each farm exhibiting the severe clinical signs including anemia, prominent keel bone, leg weakness and hemorrhages in feather follicles were humanly euthanized and postmortem examination was carried out. Morbid organs including liver, kidneys, spleen, lungs, heart, pancreas, ovary, proventriculus, intestine, skeletal muscle, cerebrum and sciatic nerves exhibiting the lesions were collected and preserved in 10% buffered formalin. As the lesions in three flocks were the same, therefore, a common picture of lesions was developed. Gross lesions were recorded.

### Histopathological Studies

Morbid organs were collected and preserved as mentioned above to prevent postmortem changes and for fixation. The tissues were completely immersed in formalin solution and kept for 10 days at room temperature for proper fixation. Then tissues were subjected to washing, dehydration in ascending concentrations of alcohol, clearing in xylene, impregnation and embedding in paraffin (Bancroft and Gamble, 2008). Then the tissues were subjected to paraffin sectioning. Briefly, 4-5 µm thick sections were stained with hematoxylin and eosin staining technique (Magouz *et al.*, 2018). Slides were examined for histopathological changes by two pathologists, and if any difference was found, a third pathologist was consulted for opinion.

### Molecular Detection

DNA was extracted from liver, spleen and tumor tissue of infected birds using standard phenol chloroform isoamyl alcohol protocol (Sambrook and Russell, 2001). For molecular detection and confirmation of virus, DNA was extracted from liver, kidneys, oviduct and spleen of morbid and dead birds. The viral DNA was isolated using TRIZOL® reagent method (Jackwood *et al.*, 2007). The ALV-J-specific primers of avian leukosis virus using F; 5'-GAAGCAGACAATAGGACTGG-3' and R; 5'-TTGACCTAGGGTATCCATCTC-3' were carried out targeting the ALV-J genes and for the confirmation of samples. The PCR was performed using Master Mix (Invitrogen, USA) and following the PCR program as described earlier (Xu *et al.*, 2004). The PCR reaction consisted of deionized water (30 µL), 10x buffer (5 µL), 200 mM each dNTP (2 µL), Taq DNA polymerase (1 µL), primers (2 µL) and DNA template (2 µL) in a total of 42 µL volume. The PCR product was run on 1% agarose gel for electrophoresis and visualized through Gel Documentation System (Dolphin Doc, USA) (Zahid *et al.*, 2018).

## Data Analysis

Data thus collected were subjected to statistical analysis applying the Chi-square test, using the Minitab statistical software package (Anonymous, 2000). The significance level was  $P < 0.05$ .

## Results

### Physical Parameters

Fayoumi layers morbidity and mortality ranged from 30-45% (with an average 37.75% and 2.27-20% (5.38% average), respectively (Table 1). Morbidity and mortality varied significantly ( $P < 0.001$ ) among farms. Similarly, egg production and hatchability ranged varied significantly ( $P < 0.001$ ) among farms (Table 1).

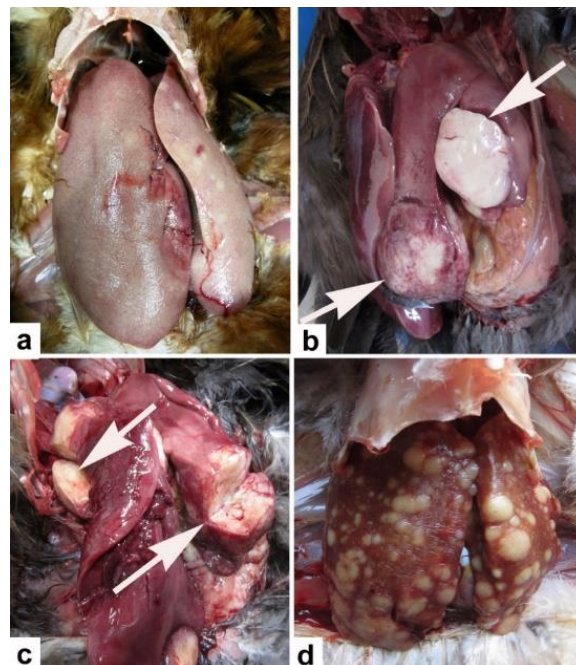
### Clinical Signs

Avian leukosis infection rendered various clinical signs such as emaciation with prominent keel bones, lethargy, somnolence, leg weakness and roughened feather were frequently observed in birds of Fayoumi layer present at all the farms. Severe anemic and pale combs were the characteristic feature in affected birds.

### Necropsy Findings

The necropsy examination revealed big liver occupied the entire abdominal cavity in most of the infected birds (Fig. 1a). In some birds, whitish solid nodules over the dorsal and ventral surfaces of hens were observed (Fig. 1b). The liver was hard in consistency, borders were sharp (Fig. 1c), color lighter with widespread necrotic areas with whitish appearance were present on the dorsal and ventral surface of the liver (Fig. 1d).

Abdomen of the birds was fully packed with distended intestinal segments and the multiple nodular adenocarcinoma (Fig. 2a). Entire serosal surface of the intestines and uterine tube was covered with numerous well circumscribed encapsulated macro and micro nodules with hard consistency (Fig. 2b). The spleen with marbling appearance was enlarged and cut surface was granular. From the cut surface of spleen, prepared impression smears did not yield any spirochetes but heavy population of neoplastic cells. Bursae were enlarged and appeared as whitish nodular mass (Fig. 2c), similar



**Fig. 1:** Grossly liver of avian leukosis virus affected birds. a) Big liver, round edges and multiple white area of necrosis, b) well circumscribed and nodules over the dorsal as well as ventral surface (arrows), c) cut surface of the nodule (arrows) and d) multiple whitish nodules of variable size present throughout dorsal and ventral surfaces even extended to the parenchyma

extension just cranial to the ovarian clutch was also observed (Fig. 2d). Kidneys were markedly swollen, bulges out from bony sockets and some had light grey/white mottled tumors.

### Histopathology

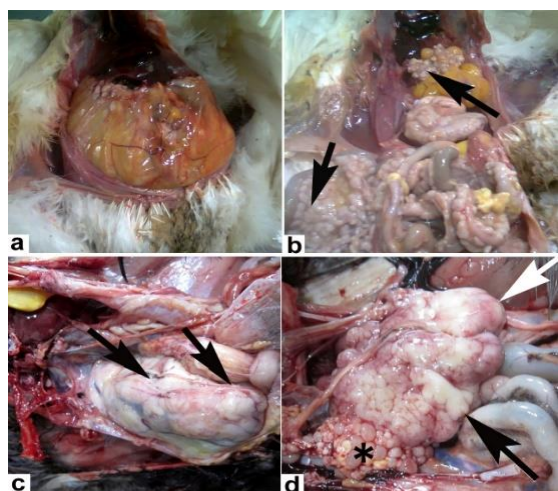
Histopathological examination of the tissue sections prepared from avian leukosis virus affected tissues showed complete organization destruction. Masses of specialized cells, *i.e.*, myelocytes with large nuclei with peripheral location and cytoplasm was studded with eosinophilic granules were present in the affected tissues (Fig. 3a). In the affected areas, monstrous macrophages were seen engulfing the necrotic cells (Fig. 3b).

The liver sections were studded with neoplastic cells, parenchyma of liver was destroyed while few healthy hepatocytes were trapped in islands of hepatocytes and putting pressure on hepatocytes thus becoming atrophied

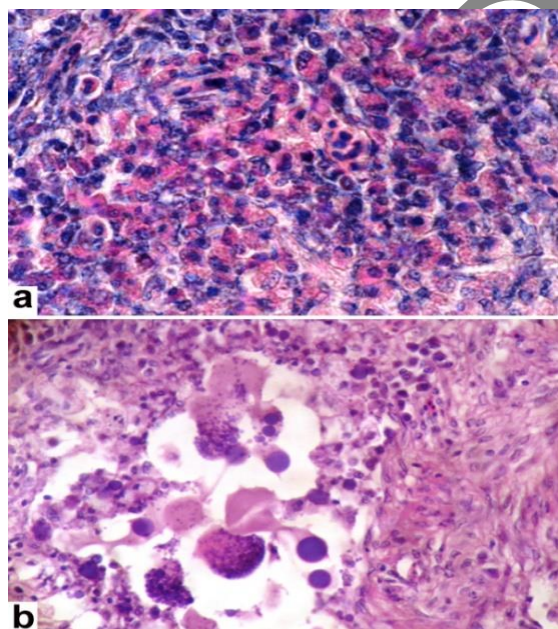
**Table 1:** Morbidity, mortality, egg production and hatchability of Fayoumi layers as a result of avian leukosis

Farm	Morbidity		Mortality		Egg Production		Hatchability	
	No.	%	No.	%	No.	%	No.	%
I (n = 6000)	1800	30	225	3.75	4200	70	2730	65
II (n = 11000)	4400	40	250	2.27	6600	60	4620	70
III (n = 3000)	1350	45	600	20.0	1650	55	990	60
Total(n= 20000)	7550	37.75	1075	5.38	12450	62.25	8540	68.6
Chi-Sq Value	112.778		1215.833		55.988		55.389	

First two farms are from Toba Tek Singh while third one from Faisalabad. Data analysis by Chi-square test and df in each case was 2 and  $P \leq 0.001$

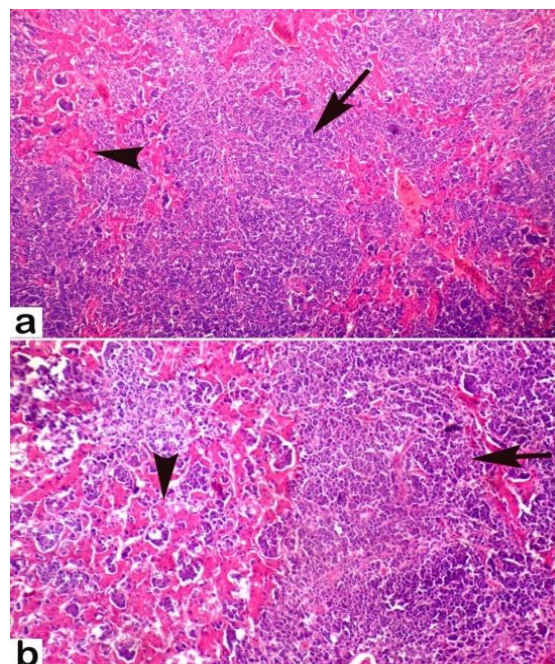


**Fig. 2:** Gross appearance of organs of avian leukosis virus affected birds. a) Abdomen of the layer is fully packed with distended intestinal segment and the multiple nodular adenocarcinoma, b) multiple well circumscribed white color nodules diffusely spread throughout the mesentery and implanted over serosal surface and metastasized to the ovarian clutch (arrows), c) significant enlargement of bursa of Fabricius (arrows) and d) a pedunculated white color mass present adjacent to the ovarian clutch (arrow) and normal ovarian follicles (asterisk)



**Fig. 3:** Characteristic myelocytes with abundant cytoplasm containing eosinophilic granules and eccentric nucleus (a) and monstrous macrophages engulfing the necrotic cells (b). H & E Stain. a=1000x, b=400x

(Fig. 4a and b). Cells of myeloblastic series with prominent nucleus and less cytoplasm invaded liver parenchyma. There was necrosis of hepatocytes along with diffuse and focal



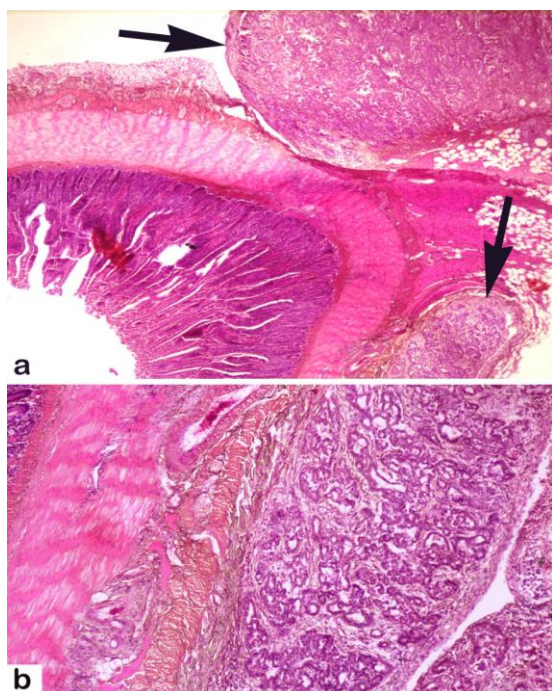
**Fig. 4:** Histopathology of avian leukosis virus affected liver. Fronts of neoplastic cells with characteristic myeloblastic series having less cytoplasm but prominent nucleus invading parenchyma (arrow) and leaving some normal areas (arrow head). H & E Stain. a=100x, b=200x

infiltration of uniform sized lymphoid cells, lymphoblasts, and round mononuclear cells. Mitotic figures were frequent in infected tissues. Hyperplasia of the bile ducts with massive infiltration of the mononuclear cells in the portal areas around the blood vessels and obliteration of the sinusoidal spaces were also observed. The epithelial linings of most of the bile ducts were degenerated and necrotic. Portal veins were engorged with erythrocytes.

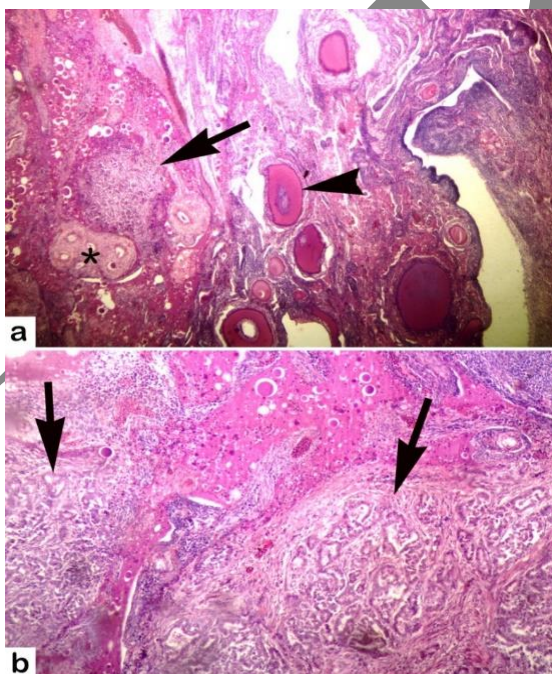
The tissue sections from affected spleen showed less population of lymphocytes and increased tumor cells in both the red pulp and the white pulp destroying the normal histological arrangement of splenic cells.

All layers of intestines were invaded by neoplastic cells (Fig. 5a and b). Inter-villus spaces were also infiltrated with neoplastic cells. Villi became denuded with the sloughing of epithelial cells along with hemorrhages and necrosis. There was massive population of neoplastic proliferation in the form of clusters with higher number of mitotic figures destroying the bursal follicular pattern (Fig. 5b). In the heart, multifocal aggregates of myelocytes were observed in the myocardium and covered by the pericardium.

Ovary sections were characterized by invasion of normal tissue by homogenous population of lymphoblasts, myeloblastic cells/myelocytes in the stromal layer underneath the granulosa cells. Moreover, well circumscribed embedded mass of metastatic adenocarcinoma among the ovarian clutch, thick tunica muscularis with onion



**Fig. 5:** Histopathology of avian leukosis virus induced a) pancreatic adenocarcinoma, a stalked over the serosal surface of intestines and encapsulated area containing multiple ductules of variable sizes (arrows) and b) area indicated with lower arrow in Fig. 4a is magnified. H & E Stain. a=100x, b=400x



**Fig. 6:** Histopathology of ovarian tissue infected avian leukosis virus. Well circumscribed embedded mass of metastatic adenocarcinoma among the ovarian clutch (arrow), thick tunica muscularis with onion pattern arrangement (asterisk) and some normal follicle (arrow head). H & E Stain. a=100x, b=400x

pattern arrangement (Fig. 6a and b) was observed. Different stages of cavernous hemangiomas were recorded in ovary sections (Fig. 6b). A few normal follicles were also seen (Fig. 6a).

### Molecular Diagnosis

The PCR confirmed avian leukosis virus by amplification of specific and conserved fragment (ALV-J-specific primers H5/H7) gene. The amplicon of ALV-J yielded 545bp PCR product (Fig. 7).

### Discussion

Avian leukosis causes severe economic losses in the layer, broiler breeders and backyard poultry. In spite of successful eradication programs and extensive control measures, avian leukosis due to subgroup J virus induces huge losses to poultry industry throughout the world (Fadly and Smith, 1999; Malkinson *et al.*, 2004; Thapa *et al.*, 2004). Various reports are available about the incidence of avian leukosis in various regions of the world (Wang and Juan, 2002; Chen *et al.*, 2005; Sun and Cui, 2007; Gopal *et al.*, 2012).

The present study describes the gross and microscopic lesions induced by naturally occurring ALV-J infections in Fayoumi laying birds in Pakistan. At postmortem examination, extensive liver enlargement with multiple nodular and raised areas on entire surface of the liver and splenomegaly was observed. Cut surface of the spleen showed marbling appearance. In Chinese commercial layer chicken due to naturally occurring avian leukosis infection, swollen kidneys along with hemorrhagic thymus, muscle and glandular stomach are described (Wang and Juan, 2002; Xu *et al.*, 2004). In present study, extensive metastasis in liver, spleen and thymus were also reported in ALV-J infection in chickens (Pandiri *et al.*, 2009; Payne and Nair, 2012) and avian leukosis virus fowl glioma (Hatai *et al.*, 2005). Nodular tumors due to this infection have also been reported in turkeys infected with acute transforming ALV-J strain 966 (Venugopal *et al.*, 2000). Enlarged lymphoid nodules in the bursa Fabricius are considered pathognomonic for lymphoid leukosis.

In the present study, histopathologically liver revealed extensive neoplastic cells infiltrating in the parenchyma along with cells of myeloblastic series having with projecting nucleus, scant cytoplasm. Neoplastic cells were also seen in red pulp and the white pulp of the spleen. Similar neoplastic cells infiltrated in various layers of intestines, similarly uterine walls were extensively infiltrated with neoplastic cells. Infiltration of neoplastic cells could be due to mutational changes in the  $\beta$ -cells of the follicles of the bursa of Fabricius which might result in switch on the oncogenes and inhibiting the tumor suppressor genes by viral genome. It could also be due to the enhanced production of oncogenic proteins and enhanced cell proliferation or growth promoting Ras PI (3) and m-TOR signaling along with their effectors

including raf, ERK family (Fung *et al.*, 1983). Moreover, uniform population of lymphoblast with large vesicular nuclei and basophilic cytoplasm were infiltrating in infected tissues. Previously, the diffuse and distinct nodular pattern of such types of tumors has been reported (Gopal *et al.*, 2012).

The tissue sections from infected livers revealed extensive loss of hepatocytes and bile duct hyperplasia with infiltration of solid sheets of lymphoblast. Similarly, other organs showed massive infiltration of tumorous cells in the hepatic parenchyma, blood vessels and myeloid areas (Venugopal *et al.*, 2000; Gingerich *et al.*, 2002). Previously, in the bursa Fabricius, lymphoid follicles at early stages showed proliferations of lymphoblasts and infiltration of differentiated myelocytes and erythroblasts due to ALV-J-infection in turkeys (Venugopal *et al.*, 2000; Payne and Nair, 2012). Recently, from Pakistan, avian leukosis infection in commercial egg laying birds without symptoms/clinical signs has been reported (Akram *et al.*, 2012).

The confirmation of avian leukosis virus infection, in the present study, was carried out using PCR. The amplicon of ALV-J yielded 545bp PCR product. Previously, avian leukosis virus infected birds with tumors in oviduct, liver, spleen and kidneys have also been confirmed (Xu *et al.*, 2004). Previously, various techniques including immunohistological localization, amplification of the genome through PCR, nested PCR and sequence analysis of PCR products of avian leukosis virus have been used for confirmation of the virus (Stedman *et al.*, 2001; Davidson and Borenshtain, 2002; Zeng *et al.*, 2014). Evidence of variation in susceptibility of avian leukosis within different breeds of chickens and layers is available (Smith *et al.*, 1998; Bacon *et al.*, 2004).

This is the first ever study about the naturally occurring avian leukosis caused by ALV-J virus in commercial Fayoumi layer in Pakistan. Further investigations are suggested regarding evolutionary relationships between different species of virus through nucleotide analysis and construction of phylogenetic trees. The presence of the leukosis in inbred laying birds brought a new challenge to the poultry industry and may inflict significant economic losses. Therefore, virus screening and elimination should be made to eradicate the disease in the region.

## References

- Akram, M., A. Khan, N. Khatoun, N.U. Nisa and M. Sayed, 2012. Lymphoid leucosis in chicken – histopathology of spleen. *Pak. J. Zool.*, 44: 596–597
- Anonymous, 2000. *MINITAB Statistical Software for Windows, Release 13 (2000)*. Minitab Inc., Pennsylvania, USA
- Arshad, S.S., K. Howes, G.S. Barron, L.M. Smith, P.H. Russell and L.N. Payne, 1997. Tissue tropism of the HPRS-103 strain of J subgroup avian leukosis virus and of a derivative acutely transforming virus. *Vet. Pathol. Online*, 34: 127–137
- Bacon, L.D., J.E. Fulton and G.B. Kulkarni, 2004. Methods for evaluating and developing commercial chicken strains free of endogenous subgroup E avian leukosis virus. *Avian Pathol.*, 33: 233–243
- Bancroft, J.D. and M. Gamble, 2008. *Theory and Practice of Histological Techniques*, 5<sup>th</sup> edition. Churchill Livingstone Publications, Edinburgh, UK
- Chen, Z., L. Zhang, S. Liu, L. Zhang and Z. Cui, 2005. Emerging of avian leukosis virus subgroup J in a flock of Chinese local breed [in Chinese]. *Wei Sheng Wu Xue Bao*, 45: 584–587
- Davidson, I. and R. Borenshtain, 2002. The feather tips of commercial chickens are a favorable source of DNA for the amplification of Marek's disease virus and avian leukosis virus, subgroup J. *Avian Pathol.*, 31: 237–240
- Dong, X., P. Zhao, B. Xu, J. Fan, F. Meng, P. Sun, S. Ju, Y. Li, S. Chang, W. Shi and Z. Cui, 2015. Avian leukosis virus in indigenous chicken breeds China. *Emerg. Microbes Infect.*, 4: e76
- Fadly, A.M., 2000. Isolation and identification of avian leukosis viruses: A review. *Avian Pathol.*, 29: 529–535
- Fadly, A.M. and E.J. Smith, 1999. Isolation and some characteristics of a subgroup J-like avian leukosis virus associated with myeloid leukosis in meat-type chickens in the United States. *Avian Dis.*, 43: 391–400
- Farooqi, S.H., M. Ijaz, M.I. Rashid, A.I. Aqib, Z. Ahmad, M.H. Saleem, K. Hussain, S. Islam, H. Naem and A. Khan, 2017. Molecular epidemiology of *Babesia bovis* in bovine of Khyber Pakhtunkhwa, Pakistan. *Pak. Vet. J.*, 37: 275–280
- Fung, Y.K., W.G. Lewis, L.B. Crittenden and H.J. Kung, 1983. Activation of the cellular oncogene c-erbB by LTR insertion: molecular basis for induction of erythroblastosis by avian leukosis virus. *Cell*, 33: 357–368
- Gingerich, E., R.E. Porter, B. Lupiani and A.M. Fadly, 2002. Diagnosis of myeloid leukosis induced by a recombinant avian leukosis virus in commercial white leghorn egg laying flocks. *Avian Dis.*, 46: 745–748
- Gopal, S., P. Manoharan, K. Kathaperumal, B. Chidambaram and K.C. Divya, 2012. Differential detection of avian oncogenic viruses in poultry layer farms and turkeys by use of multiplex PCR. *J. Clin. Microbiol.*, 50: 2668–2673
- Hatai, H., K. Ochiai, Y. Tomioka, T. Toyoda, K. Hayashi, M. Anada, M. Kato, A. Toda, K. Ohashi, E. Ono, T. Kimura and T. Umemura, 2005. Nested polymerase chain reaction for detection of the avian leukosis virus causing so-called fowl glioma. *Avian Pathol.*, 34: 473–479
- Jackwood, M.W., D.A. Hilt, S.M. Williams, P. Woolcock, C. Cardona and R.O'Connor, 2007. Molecular and serologic characterization, pathogenicity, and protection studies with infectious bronchitis virus field isolates from California. *Avian Dis.*, 51: 527–533
- Khan, A., R. Sharaf, M.Z. Khan, M.K. Saleemi and F. Mahmood, 2013. Arsenic toxicity in broiler chicks and its alleviation with ascorbic acid: a toxico-patho-biochemical study. *Intl. J. Agric. Biol.*, 15: 1105–1111
- Khan, M.N., M.S. Sajid, H.M. Rizwan, A. Qudoos, R.Z. Abbas, M. Riaz and M.K. Khan, 2017. Comparative efficacy of six anthelmintic treatments against natural infection of fasciola species in sheep. *Pak. Vet. J.*, 37: 65–68
- Kilany, W.H., M.A. Soliman, M.A. Safwat, O. Mehana, M.A. El-Magid, M.K. Hassan and S.A. Nasif, 2015. Detection of avian leukosis virus subgroup J from commercial Peking duck breeder farm in Egypt. *Intl. J. Virol.*, 2015. DOI: 10.3923/ijv.2015
- Landman, W.J., J. Post, A.G. Boonstra-Blom, J. Buyse, A.R. Elbers and G. Koch, 2002. Effect of an *in ovo* infection with a Dutch avian leukosis virus subgroup J isolate on the growth and immunological performance of SPF broiler chickens. *Avian Pathol.*, 31: 59–72
- Magouz, A., W. Abdo, A. Abdelsabour, A. Elbestawy and A. Desouky, 2018. Molecular and histopathological investigation of avian infectious bronchitis virus in the delta of Egypt between 2016 and 2017. *Pak. Vet. J.*, 38: 243–248
- Malkinson, M., C. Banet-Noach, I. Davidson, A.M. Fadly and R.L. Witter, 2004. Comparison of serological and virological findings from subgroup J avian leukosis virus-infected neoplastic and non-neoplastic flocks in Israel. *Avian Pathol.*, 33: 281–287
- Padhi, M.K., 2016. Importance of indigenous breeds of chicken for rural economy and their improvements for higher production performance. *Scientifica (Cairo)* 2016: 2604685. DOI: 10.1155/2016/2604685
- Pandiri, A.R., I.M. Gimeno, W.M. Reed, S.D. Fitzgerald and A.M. Fadly, 2009. Subgroup J Avian leukosis virus-induced histiocytic sarcomatosis occurs only in persistently viremic but not immunotolerized meat-type chickens. *Vet. Pathol.*, 46: 282–287

- Payne, L.N. and V. Nair, 2012. The long view: 40 years of avian leukosis research. *Avian Pathol.*, 41: 11–19
- Reinišová, M., J. Plachý, D. Kučerová, F. Šenigl, M. Vinkler and J. Hejnar, 2016. Genetic Diversity of NHE1, receptor for subgroup J avian leukosis virus, in domestic chicken and wild anseriform species. *PLoS One*, 11: e0150589
- Sagarika, S., D. Das, S.K. Panda, S. Das, B. Jena and R.K. Sahu, 2017. Avian leukosis in chickens: A Clinico-pathological survey. *J. Entomol. Zool. Stud.*, 5: 1697–1701
- Sambrook, J. and D.W. Russel, 2001. *Omic Preparation and Analysis of Eukaryotic Genomic DNA. In: Molecular Cloning A Laboratory Manual*, pp: 6.4–6.11, Vol. 1. Sambrook, J. and D.W. Russel (eds.). Cold Spring Harbor, New York
- Shah, M.K., U. Saddique, S. Ahmad, A. Iqbal, A. Ali, W. Shahzad, M.S. Khan, H. Khan, H.U. Rehman, S.S.A. Shah and M. Israr, 2017. Molecular characterization of local isolates of *Mycoplasma capricolum* sub specie *Capri pneumoniae* in goats (*Capra hircus*) of Khyber Pakhtunkhwa, Pakistan. *Pak. Vet. J.*, 37: 90–94
- Smith, L.M., S.R. Brown, K. Howes, S. McLeod, S.S. Arshad, G.S. Barron, K. Venugopal, J.C. McKay and L.N. Payne, 1998. Development and application of polymerase chain reaction (PCR) tests for the detection of subgroup J avian leukosis virus. *Vir. Res.*, 54: 87–98
- Sohaib, M. and F. Jamil, 2017. An insight of meat industry in Pakistan with special reference to halal meat: A comprehensive review. *Kor. J. Food Sci. Anim. Resour.*, 37: 329–341
- Stedman, N.L., T.P. Brown and C.C. Brown, 2001. Localization of avian leukosis virus subgroup j in naturally infected chickens by RNA *in situ* hybridization. *Vet. Pathol.*, 38: 649–656
- Sun, S. and Z. Cui, 2007. Epidemiological and pathological studies of subgroup J avian leukosis virus infections in Chinese local “yellow” chickens. *Avian Pathol.*, 36: 221–226
- Swathi, B., A. Kumar and M.R. Reddy, 2012. Histological and molecular diagnosis of poultry tumours. *Ind. J. Vet. Pathol.*, 36: 41–48
- Thapa, B.R., A.R. Omar, S.S. Arshad and M. Hair-Bejo, 2004. Detection of avian leukosis virus subgroup J in chicken flocks from Malaysia and their molecular characterization. *Avian Pathol.*, 33: 359–363
- Venugopal, K., K. Howes, D.M.J. Flannery and L.N. Payne, 2000. Subgroup J avian leukosis virus infection in turkeys: Induction of rapid onset tumours by acutely transforming virus strain 966. *Avian Pathol.*, 29: 319–325
- Wang, C.H. and Y.W. Juan, 2002. Occurrence of subgroup J avian leukosis virus in Taiwan. *Avian Pathol.*, 31: 435–439
- Witter, R.L., I.M. Gimeno and A.M. Fadly, 2005. *Differential Diagnosis of Lymphoid and Myeloid Tumors in the Chicken*, pp: 1–49, AAAP Slide Study Set #27 American Association of Avian Pathologists, Athens, GA (2005) (Electronic media)
- Xu, B., W. Dong, C. Yu, Z. He, Y. Lv, Y. Sun, X. Feng, N. Li, L.F. Lee and M. Li, 2004. Occurrence of avian leukosis virus subgroup J in commercial layer flocks in China. *Avian Pathol.*, 33: 13–17
- Zahid, B., A. Aslam, R. Anjum, S. Imran, I. Irshad, C. Ara and H. Sadia, 2018. Study on tissue tropism and molecular detection of vp2 gene of infectious bursal disease virus in experimentally infected broiler tissues. *Pak. Vet. J.*, 38: 291–295
- Zeng, X., L. Liu, R. Hao and C. Han, 2014. Detection and molecular characterization of J subgroup avian leukosis virus in wild ducks in China. *PLoS One*, 9: e94980. DOI: 10.1371/journal.pone.0094980

(Received 20 March 2019; Accepted 22 April 2019)