



**Full Length Article**

## Evaluation of Efficacy of Compound Chinese Medicinal Herbs against *Mycoplasma synoviae* using different Lab Tests in Mouse and Chicken

Atif Rehman<sup>1</sup>, Hu Hesheng<sup>1\*</sup>, Muhammad Aziz ur Rahman<sup>2</sup>, Xu Jingyi<sup>1</sup>, Liu Shuang<sup>1</sup>, Guo Yannan<sup>1</sup> and Sajid Hussain Qamar<sup>3</sup>

<sup>1</sup>College of Agriculture, Department of Veterinary Science, Ningxia University, Ningxia Hui Autonomous Region Yinchuan, China

<sup>2</sup>Institute of Animal and Dairy Sciences, University of Agriculture, Faisalabad

<sup>3</sup>Institute of Animal Nutrition, Key Laboratory for Animal Disease-Resistance Nutrition of China, Ministry of Education, Sichuan Agricultural University, Chengdu, Sichuan, China, 611130

\*For Correspondence: heshenghu308@163.com; Cell# 008615009407407; 2100435737@qq.com

### Abstract

The present study was designed to treat the *Mycoplasma synoviae* (MS) by Chinese herbs extract (CHE). In the current study, prepared drug sensitivity and safety test was carried out by culture medium and on mice model against MS, respectively. The sensitivity test results showed that the sensitivity of MS towards *Rheum rhabarbarum* and *Lysimachia davurica* was highest, followed by the *Lonicera japonica*, *Codonopsis pilosula* and *Radix liquiritiae*. Drug safety experiment results showed that LD<sub>50</sub> of the compound Chinese medicine preparation was 41438 mg/kg. For chicken pathological model, 50 six-week old chicks were divided into five groups. First group was considered as a negative control group, sec group was considered as a positive control (infected with MS), 3<sup>rd</sup> group infected with MS and supplemented with CHE @ 2 mL/bird/day, 4<sup>th</sup> group infected with MS and supplemented with CHE @ 1.5 mL/bird/day and 5<sup>th</sup> group infected with MS and supplemented with CHE @ 1 mL/bird/day for 3 days, respectively. In chicken pathological model, results of ELISA and culture medium test showed that group 3 had a better recovery response towards MS. The results of ELISA showed that the MS were found in each group at day 3. At 6 and 9 day, 4<sup>th</sup> and 5<sup>th</sup> group showed MS sign. At day 12, 3<sup>rd</sup> and 4<sup>th</sup> group didn't show any MS sign. At day 15 and 18, no MS signs were observed in all groups. Based on findings, it is concluded that Chinese herbal medicine @ 2.5 mL/bird showed a better resistance towards MS. © 2019 Friends Science Publishers

**Keywords:** *Mycoplasma synoviae*; Chinese medicinal herbs; Sensitivity test; Drug safety testp; Chicken pathological model

### Introduction

*Mycoplasma synoviae* (MS) cause acute or chronic infectious disease, which is characterized by synovitis, sinusitis and arthritis in poultry birds (Olson *et al.*, 2004). The involvement of respiratory and central nervous system may lead to dropped egg production and mortality, causing huge losses to poultry industry (Ding *et al.*, 2015; Senthilnathan *et al.*, 2015). *Mycoplasma synoviae* belongs to mollicute genus of bacteria that lack a cell wall around their cell membranes. This characteristic makes them naturally resistant to many common antibiotics such as penicillin or other beta-lactam antibiotics that target cell wall synthesis. Moreover, residual effect of antibiotics in the meat is major threat to poultry industry (Lauderdale *et al.*, 2007). Many countries have banned the addition of antibiotics in the feed of poultry due to residual effects (Lauderdale *et al.*, 2007; Angulo *et al.*, 2009). Therefore, scientists are looking for alternatives of antibiotics as growth promoters (Lauderdale *et al.*, 2007;

Angulo *et al.*, 2009) as looking for other forage sources for better livestock production (Rahman *et al.*, 2017; Muhammad *et al.*, 2019). It has been reported that pharmacologically active substances in herbal plants have potential for growth improvement in poultry health and production (Tamara *et al.*, 2009; Farhat *et al.*, 2011). Herbs like *Rheum rhabarbarum* (Rhubarb), *Lysimachia davurica* (Loosestrife), and *Codonopsis pilosula* (Dang Shen) has been known for its pharmacologically active substances and are considered antimicrobial, antiulcerogenic, hepatoprotective, immunostimulant, antigenotoxic, antioxidant, antifungal, antibacterial, antiplatelet, antihypertensive, and anti-inflammatory (Mushtaq *et al.*, 2016). Gong *et al.* (2014) reported that Chinese herbs have great influence on immune response, intestinal health, nutrient metabolism and production performance of the animals. However, to date, no study reported the antibiotic effect of Chinese herbs against MS like *Rheum rhabarbarum*, *Lysimachia davurica* (Loosestrife), *Gardenia jasminoides* (Gardenia), *Lonicera*

*japonica* (Honeysuckle), *Achyranthes bidentate* (Twotoothed Achyranthes Root), *Ottelia alismoides* (Duck Lettuce), *Viola philippica* (Chinese Violet), *Anemarrhena asphodeloides bunge* (Zhi Mu), *Andrographis paniculata* (Green Chireta), *Codonopsis pilosula*, *Angelica acutiloba* (Dong Dang Gui) and *Radix liquiritiae* (Licorice root). Hence, we hypothesized that the extracts of above-mentioned Chinese herbs will have therapeutic potentials and could be good candidates for an alternative of antibiotics against MS.

## Materials and Methods

### Extraction Method of Chinese Herbs

A total of 12 Chinese herbs were used in this study, as mentioned below along with their ingredients. For extraction, Chinese herbs roots (20 g of each) were taken separately and crushed to about 40 meshes in a casserole. Crushed Chinese herbs were soaked in 200 mL purified water for 1-2 h. After that crushed Chinese herbs were boiled and decocted for 90 min. The liquid obtained was filtered with 4 layers of gauze cloth. After cooling, with 200 mL purified water was added and again boiled for 45 min. Extract was again filtered using 4 layers of gauze cloth and residues were discarded. After that, mixture was centrifuged to remove the residues. One mL of the original liquid was equivalent to 1 g of the original medicinal material (in the following test converted to mass concentration, i.e., g/mL). After that it was boiled at 100°C for sterilization. Obtained medicinal material was stored at 4°C for further use. After extraction of herbs, 1 mL of each plant material (approx. 1 g) was subjected to thin-layer chromatography (TLC) to quantify herb ingredients. The following ingredients in 12 herbs were observed: chrysophanol in *Rheum Rhabarbarum*, Berberine in *Gardenia Jasminoides*, luteolin in *Lonicera Japonica*, charcoal in *Achyranthes Bidentate*, flavonoids and alkaloids in *Ottelia Alismoides*, flavonoids and glycosides in *Viola Philippica*, terpenoid saponins in *Anemarrhena Asphodeloides Bunge*, isobaicalein in *Andrographis Paniculata*, alkaloids and Nitrogen-containing components in *Codonopsis Pilosula*, polysaccharide, volatile oil, and ferulic acid in *Angelica Acutiloba*, and glycyrrhizin in *Radix Liquiritiae*.

### Drug Sensitivity Test

Drug sensitivity test was carried out to check the efficacy of 12 herbal extracts against MS using minimum inhibitory concentration method and Oxford cup method. Briefly, aseptic snails (10) test tubes were taken against every herbal extract. In each tube, modified Frey's medium (0.9 mL) was added and then 0.1 mL bacteria were added in first tube, mixed well, then take out 0.1 mL and added to the sec tube, and so on, to the last tubes and discarded 0.1 mL at the end to maintain the volume. After that, herbal extract (0.1 mL) was added into each tube. Same dosage rate was followed for Oxford cup method. Cup was placed in the center of agar

medium and herbal extracts was added inside the cup to allow the slow penetration into the medium. Then, these test tubes and culture plates with Oxford cup were incubated in an incubator at constant temperature of 37°C. After three 3 days, the color change of the culture medium was observed. After that, the size of the bacteriostatic circle was measured to determine its sensitivity.

After sensitivity test against MS, top five most efficacious herbs were selected for safety test and *in vivo* evaluation of antibiotic activity against MS, including *Rheum Rhabarbarum*, *Lysimachia Davurica*, *Lonicera Japonica*, *Codonopsis Pilosula* and *Radix Liquiritiae*. Selected herbs were mixed with the equal proportion of each and different doses were prepared, as indicated in each assay.

### Herbal Extracts Safety Test

Mice (196 ICR) used in the all test were procured from the Animal Experimental Center of Ningxia Medical University (Ningxia, Yinchuan city). In all tests, it was ensured that mice were of 7 weeks old and have 50:50 male and female ratio with average weight of 20g. In the current test, 48 mice were randomly divided into six groups in such a way that each group contained eight mice. Mice were kept in special cages and ensured to take feed and enough water during adaptation period for 5 days. Before the experiment, mice were kept on fasting for 12-16 h and had only access to drinking water. Before 4 h of experiment, complete fasting was ensured.

### Drug Preparation for Safety Test

Compound drug of top five selected Chinese herbs (based on previous sensitivity) was prepared by 100% of the liquid medicine (1 mL solution contained 1 g of the original drug).

### Pre-experimental Dosage Calculation

In current test, 48 mice were used and experimental groups as described in the previous test. The experimental groups were injected with compound herbal extracts @ 10000, 20000, 40000, 80000 and 160000 mg/kg body weight, respectively. Drug was injected in mice intraperitoneally using 12 gauge needle and estimated lethal dose ( $D_{min}$  and  $D_{max}$ ) was determined using following formula:

$$i = (\log D_{max} - \log D_{min}) / (n-1)$$

### Acute Toxicity Test of Mice

One hundred mice (ICR) were randomly divided into 10 groups in such a way that each group contained 10 mice. One group was considered control group and other nine were considered as experimental groups. Each group was injected with compound herbal extracts according to the pre-experimental calculation of the dose of intraperitoneal injection. After 4 h and 30 min of administration of herbal extracts, mice were observed for physical examination for 7 days and number of died mice was recorded. The state of

hyperactivity or depression, the sensitivity to external stimulation, the smoothness of coat, the presence of corneal hemorrhage, redness and swelling were also recorded. Respiratory frequency and breathing depth, abnormal activity, and defecation were observed after poisoning death in mice, to observe whether the tissues, organs and mucosa of the mice had changed. The median lethal dose (Idris *et al.*, 2016) ( $LD_{50}$ ) was calculated according to the modified Cox method.

### Chicken Pathological Model

In current test, six-week-old chicks were infected with MS by respiratory tract infection. For this purpose, chicks were divided five groups in such a way that each group contained 10 chicks. In each group, each chicken was reared in individual cage. First group was considered as a negative control group (blank), sec group was considered as a positive control (infected with MS and without herbal extracts treatment) and the remaining three groups were considered as experimental groups. Experimental groups were infected by the MS and treated with compound herbal extracts supplementation. Experiential group 3 was supplemented with Chinese herbal extract @ 2 mL/bird/day, experiential group 4 was supplemented with Chinese herbal extract @ 1.5 mL/bird/day and experiential group 5 was supplemented with Chinese herbal extract @ 1 mL/bird/day for 3 days, respectively. The actual amount of herbal extract administrated to each bird in each group was 6mL/bird for experimental group 3, 4.5 mL/bird for experimental group 4 and @ 3 mL/bird for experimental group 5. *Mycoplasma Synoviae* bacteria (0.5 mL) were injected through the respiratory tract for three days. After infection, the temperature of the chicken through anus was measured every day. The blood was collected after every three days (day 3, 6, 9, 12, 15 and 18) after the infection. Blood serum was separated and frozen at  $-80^{\circ}\text{C}$ . After 18 d of infection, the chickens were examined, and samples were collected. The joint fluid and visceral tissues were attached to the Frey's liquid medium. The purified culture was partially amplified by PCR to detect whether the expected size could appear. A part was attached to the Frey solid medium, and the sterile growth condition was observed after 3 days. After, 18 days of infection the compound herbal extract was given to the birds for 3 days through drinking water. The treatment plan is in the following table. After 1<sup>st</sup>, 2<sup>nd</sup> and 3<sup>rd</sup> weeks of treatment, one bird from each group was slaughtered. Internal parts of slaughtered birds were examined for any difference between controls and treatment groups. The ELISA and PCR test were carried out after infection with MS and after treating with herbal extracts. Difference of both values was calculated to check the efficacy of herbal extract.

### Statistical Analysis

Data were analyzed by using Analysis of Variance (ANOVA) Technique and completely randomized design was employed.

Least significance difference was used to compare treatment means differences.

## Results

### The Bacteriostatic Effect of Chinese Herbal Extract against *Mycoplasma synoviae* by Minimum Inhibitory Concentration Method

The result of twelve Chinese herbal extract antimicrobial activity against *Mycoplasma synoviae* by minimum inhibitory concentration method is presented in supplementary Table 1. Five Chinese herbal extract (*Rheum rhabarbarum*, *Lysimachia davurica*, *Lonicera japonica*, *Codonopsis pilosula* and *Radix liquiritiae*) elicited a strong antibacterial effect with bacteriostatic range values between 0.0313 to 0.1250 mg/mL. The bacteriostatic range values of *Gardenia jasminoides*, *Achyranthes bidentate*, *Ottelia alismoides*, *Viola philippica*, and *Angelica acutiloba* were 0.2500 mg/mL and showed moderate antibacterial effect. However, *Anemarrhena asphodeloides bunge* and *Andrographis paniculata* had no antibacterial effect with bacteriostatic range values of 0.5000 mg/mL.

### The Bacteriostatic Effect of Chinese Herbal Extract against *Mycoplasma synoviae* by Oxford Cup Method

The result of twelve Chinese herbal extract antimicrobial activity against *Mycoplasma synoviae* by Oxford cup method is presented in Table 1. Five Chinese herbal extract (*Rheum rhabarbarum*, *Lysimachia davurica*, *Lonicera japonica*, *Codonopsis pilosula* and *Radix liquiritiae*) elicited a strong antibacterial effect with an inhibition zone of more than 24 mm. The inhibition zones of *Gardenia Jasminoides*, *Achyranthes Bidentate*, *Ottelia Alismoides*, *Viola Philippica*, and *Angelica Acutiloba* were greater than 14 mm but less than 24 and showed moderate antibacterial effect. However, *Anemarrhena asphodeloides bunge* and *Andrographis paniculata* had no antibacterial effect with an inhibition zones of 8.00 mm.

### Acute Toxicity Test in Mice

Experimental results of acute toxicity of intragastric injection is given in Table 2. Of the tested mice, no fatality occurred during post-administration even at a dose of 10000 mg/kg, indicating that the minimal lethal dose of Chinese herbal extract in mice exceeds 10000 mg/kg. The minimum lethal dose  $D_{\min}$  for the Chinese herbal extract was 20,000 mg/kg and the maximum lethal dose  $D_{\max}$  was 160,000 mg/kg in mice. The logarithmic interval  $I = 0.113$  was obtained for each experimental group. The calculated dosage by log (mg/kg body weight) for each experimental group is given in Table 2.

**Table 1:** The bacteriostatic effect of Chinese herbal extract against *Mycoplasma synoviae* by Oxford cup method

Chinese herbal extract	Inhibition zone (mm) of <i>Mycoplasma synoviae</i>	Bacteriostatic effects <sup>1</sup>
<i>Rheum Rhabarbarum</i>	26.67 <sup>ab</sup> ± 0.89	Sensitive
<i>Gardenia Jasminoides</i>	13.67 <sup>c</sup> ± 1.89	Moderately sensitive
<i>Lysimachia Davurica</i>	24.83 <sup>ab</sup> ± 1.89	Sensitive
<i>Lonicera Japonica</i>	26.33 <sup>ab</sup> ± 0.89	Sensitive
<i>Achyranthes Bidentate</i>	21.17 <sup>bc</sup> ± 0.89	Moderately sensitive
<i>Ottelia Alismoides</i>	20.83 <sup>bc</sup> ± 0.56	Moderately sensitive
<i>Viola Philippica</i>	20.50 <sup>bc</sup> ± 3.04	Moderately sensitive
<i>Codonopsis Pilosula</i>	50.00 <sup>a</sup> ± 1.33	Sensitive
<i>Anemarrhena Asphodeloides Bunge</i>	08.00 <sup>c</sup> ± 0.37	Resistant
<i>Andrographis Paniculata</i>	08.00 <sup>c</sup> ± 0.35	Resistant
<i>Radix Liquiritiae</i>	24.50 <sup>ab</sup> ± 0.33	Sensitive
<i>Angelica Acutiloba</i>	14.67 <sup>c</sup> ± 3.01	Moderately sensitive

Means with different superscripts shows significant difference between 12 herbs ( $P < 0.05$ )

<sup>1</sup>The bacteriostatic effect with the oxford cup diameter > 24 were considered Sensitive, bacteriostatic effect with the oxford cup diameter < 24 but > 14 were considered Moderately sensitive and bacteriostatic effect with the oxford cup diameter < 14 were considered as Insensitive or resistant, respectively

**Table 2:** Effect of intragastric injection of Chinese herbal extract on acute toxicity test in mice

Dose (mg/kg)	Number of deaths /animals (only)	Calculated dosage by log (mg/kg body wt.)
Blank control group 0	0/8	
10000	0/8	20000
20000	0/8	25940
30000	2/8	33650
40000	2/8	43650
50000	2/8	56620
70000	5/8	73450
90000	6/8	95270
120000	6/8	123590
160000	8/8	160320

Clinical symptom of mice after intragastric injection of calculated log dosages are presented in Supplementary Table 2. Administration of calculated log dosage of Chinese herbal extract to mice revealed that mice @ 20000 mg/kg Chinese herbal extract showed normal intake, drinking and other activities after 18 h with no mortality. However, after 18 h mice received dosage of 25940 and 36650 mg/kg body weight Chinese herbal extract still showed less feed intake, and no movement with 20% mortality. Moreover, after 46 h administration of Chinese herbal extract in mice @ 95270 mg/kg, 123590 mg/kg, and 160320 mg/kg dose showed no intake and movement with 100% mortality rate. However, after 108 h after administration of Chinese herbal extract @ 20000, 25940 and 36650 mg/kg body weight, all survived mice return to normal feed intake, drinking and movement. Results of both experiments showed that LD<sub>50</sub> was >10000 mg/kg. The maximum tolerance of Chinese herbal extract was 20000 mg/kg of body weight for mice (LD<sub>0</sub> = 20000 mg/kg). The minimum lethal dose (D<sub>min</sub>) of Chinese herbal extract was 25940 mg/kg body weight, while the maximum lethal dose (D<sub>max</sub>) was 95270 mg/kg of body weight for mice. Furthermore, calculated LD<sub>50</sub> of the Chinese herbal extract was 41438 mg/kg of mice body weight.

### Chicken Model Results

**Symptom in chicken after infection of *Mycoplasma synoviae*:** Clinical symptom of birds after infected with MS are presented in Supplementary Table 3. Seven days after

inoculation of MS, infected chickens showed reduced intake, drinking and drop of feathers. After 10 days of MS infection, infected birds showed nasal discharge, cough, half closed eyes and respiratory rales. After 12 days of MS infection, infected birds were found with swollen eyelids, and pale comb. After 15 days of infection, swollen face and aggravated respiratory rale was observed in MS infected birds. Moreover, after 18 days of infection, birds had swollen leg joints and they were limping and sneezing. The clear picture of swollen spleen and joint are shown in Fig. 1 and 2.

After 48 h, attached joint fluid and visceral tissues with Frey's liquid medium changed into yellow turbid medium. The resultant liquid culture medium was transferred to the solid medium, and a colony of needle tip size (3 D at 37°C) was observed. Furthermore, under 40 times of microscope, the typical "fried egg" colony of *Mycoplasma capsularis* was observed (Fig. 3) which confirmed that the isolated pathogen was *Mycoplasma*.

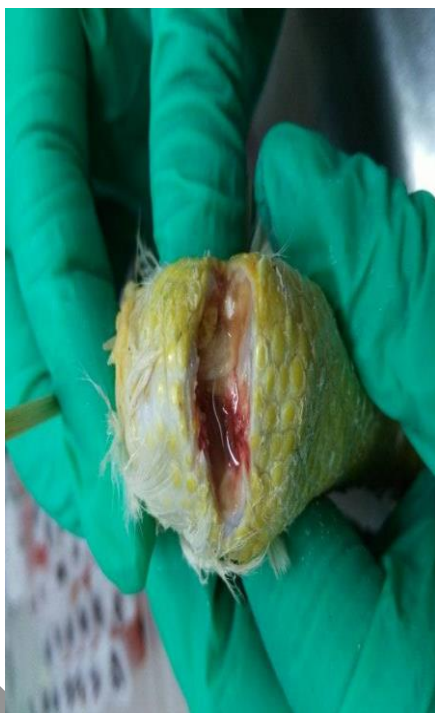### Symptoms and Recovery of *Mycoplasma synoviae* Infected Chicken after Supplementation of Herbal Extracts

Clinical symptom of infected chicken after supplementation of herbal extracts is present in supplementary Table 5. Negative control birds in chicken model was normal with no sign and symptoms of disease. However, birds of positive control were low spirited with pale comb, respiratory rales,


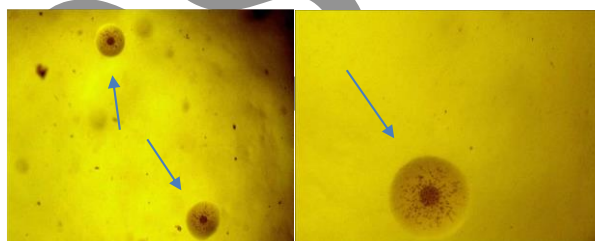
**Table 3:** Effect of Chinese herbal extract intraperitoneal injection on acute toxicity test in mice

Groups	Dosage (mg/kg body wt.)	Logarithmic dose g/kg	Number of deaths	Mortality %
1	20000	4.3010 <sup>a</sup>	0/10 <sup>a</sup>	0.0
2	25940	4.4140 <sup>a</sup>	2/10 <sup>ab</sup>	0.2
3	33650	4.5270 <sup>ab</sup>	2/10 <sup>ab</sup>	0.2
4	43650	4.6400 <sup>b</sup>	7/10 <sup>abc</sup>	0.7
5	56620	4.7530 <sup>bc</sup>	8/10 <sup>bc</sup>	0.8
6	73450	4.8660 <sup>bc</sup>	8/10 <sup>bc</sup>	0.8
7	95270	4.9790 <sup>c</sup>	10/10 <sup>c</sup>	1.0
8	123590	5.0920 <sup>c</sup>	10/10 <sup>c</sup>	1.0
9	160320	5.2050 <sup>c</sup>	10/10 <sup>c</sup>	1.0
SEM		0.064	26.738	

Means with different superscripts within a column differ significant ( $P < 0.05$ )  
SEM: Stander Error Mean

**Fig. 1:** Leg joint of bird infected with *Mycoplasma synoviae*

swollen eyelids, nasal discharge, sneezing/cough, and bird were lying on ground. At day 3, after administration of dosage of Chinese herbal extract @ 2 mL/bird/day to infected birds revealed that low spirit, pale comb, respiratory rales, swollen eyelids, and nasal discharge were decreased. Signs of disease were totally disappeared in infected birds at day 10 with Chinese herbal extract supplementation @ 2 mL/bird/day. However, infected birds supplemented Chinese herbal extract @ 1.5 and 1 mL/bird/day body weight didn't recovered completely and showed signs even at day 15 in infected birds. The lung, spleen, laryngeal tracheal mucus and joint fluid samples from every group were inoculated with Frey's liquid medium of MS (Fig. 4). The results showed that group 3 did not show any positive sign of MS in culture medium and during PCR, while other treatments group still showed *Mycoplasma* growth in culture medium.

**Fig. 2:** Comparison of spleen between positive control (Infected with *Mycoplasma synoviae*) and 3<sup>rd</sup> group (Infected with *Mycoplasma synoviae* and supplemented with Chinese herbal extract @ 2 mL/bird/day)**Fig. 3:** Appearance of *Mycoplasma synoviae* colonies on fried eggs under microscope (40×)

### Recovery of *Mycoplasma synoviae* Infected Chicken after Supplementation of Herbal Extracts Detected by ELISA

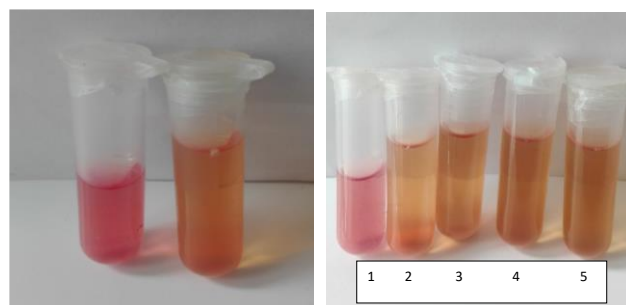
The results of the antibody test showed that experimental group 3 supplemented with Chinese herbal extracts (@ 2.5 mL/bird) had better recovery response towards MS as compared to other treatments groups. Positive sign of MS presence was found in each experimental group at day 3. At day 6 and 9 no positive sign of MS was found in experimental group 3. However, at day 6 and 9, experimental groups 4 and 5 still showed positive sign of MS presence. At day 12, experimental groups 4 showed negative sign of MS presence while experimental group 5 still showed positive sign of MS presence. At day 15 and 18, all experimental groups showed negative sign towards MS presence (Table 4). Furthermore, numerical values of recovery of *Mycoplasma synoviae* infected Chicken after supplementation of herbal is present in supplementary Table 4.

### Discussion

Herbal medicines are being used to treat various species of the animals (Ayorinde *et al.*, 2015; Fu *et al.*, 2018; Qamar *et al.*, 2019). However, before using herbal medicine in animal, safety studies are conducted by

**Table 4:** Effect of supplementation of Chinese herbal extract on presence of *Mycoplasma synovaie* at different days (Elisa results)

Groups	Days					
	3	6	9	12	15	18
Negative control	-	-	-	-	-	-
Positive control <sup>1</sup>	+	+	+	+	+	+
3 <sup>rd</sup> Experimental Group <sup>2</sup>	+	-	-	-	-	-
4 <sup>th</sup> Experimental Group <sup>3</sup>	+	+	+	-	-	-
5 <sup>th</sup> Experimental Group <sup>4</sup>	+	+	+	+	-	-

<sup>1</sup>Infected with *Mycoplasma Synovaie*<sup>2</sup>Infected with *Mycoplasma Synovaie* and supplemented with Chinese herbal extract @ 2 ml/bird/day for 3 days<sup>3</sup>Infected with *Mycoplasma Synovaie* and supplemented with Chinese herbal extract @ 1.5 ml/bird/day for 3 days<sup>4</sup>Infected with *Mycoplasma Synovaie* and supplemented with Chinese herbal extract @ 1 ml/bird/day for 3 days**Fig. 4:** Liquid medium of *Mycoplasma*. Tube 1 shows no *Mycoplasma synovaie* growth (experimental group 3). Tube 2-5 are representing *Mycoplasma synovaie* growth in positive and experimental groups 4 and 5

execution of acute and sub-acute toxicity tests in laboratory animals (Fennell *et al.*, 2004). In current study, extract mixture of five Chinese herbs were subjected to test acute and sub-acute toxicity in mice model. Results revealed that administration of a single 2000 mg/kg dose of compound Chinese herbal extract did not showed any signs of toxicity or mortality in mice. Current findings are in accordance with the previous study of Sankhari *et al.* (2010) and they reported that mice treated with herbal extract @ 15000-2500 did not show any mortality or abnormal behavior. No sign of toxicity and zero mortality @ 2000 mg/kg dose of compound Chinese herbal extract in current study represent that the LD<sub>50</sub> of compound Chinese herbal extract should be considered higher than 2000 mg/kg. According to the Globally Harmonized System (GHS) of Classification and Labelling of Chemicals, the substances having an LD<sub>50</sub> value greater than 2000 mg/kg are considered as relatively safe (Konan *et al.*, 2007). Rhiouani *et al.* (2008) also reported that the LD<sub>50</sub> values of therapeutic herbal extracts have been reasonably safe on acute exposure (Rhiouani *et al.*, 2008). In acute toxicity experiment of current mice model revealed that mice treated with compound Chinese herbal extract had no adverse effects between 2000-5000 mg/kg treated group of mice. However, treatments related adverse effects were visible in the studied parameters when administrated @ 8000-16000 mg/kg in mice. Similar findings were also observed by

Rhiouani *et al.* (2008) and they reported that extract of Moroccan traditional medicinal plant (*Herniaria glabra*) at higher dose rate cause high mortality. The findings of current study are also similar with findings of Okoye *et al.* (2012), who reported that single-dose oral administration of *Annona senegalensis* root extract in female rats @ 4000 mg/kg dose rate didn't cause any mortality in rats. Similarly, other researcher also reported same results (Satyanarayana *et al.*, 2001; Sankhari *et al.*, 2010). However, mortality is not a single indicator of adverse effects of medicine. Other factors like growth rate, liver and kidney weight could be other indicator of adverse effects of medicine. The liver and the kidneys are target organs for toxic chemicals due to their essential functions in bodily detoxification and excretion processes (Hall, 2001). Thus, liver and kidney should be considered in toxicity studies because of their sensitivity to harmful compounds and their potential to predict toxicity (Amna *et al.*, 2013).

Results of chicken model represents that Chinese herbal extracts recovered MS infected birds. Findings are in according with the study of Ayorinde *et al.* (2017) and Fu *et al.* (2018). They reported that herbal extracts enhance the immunity level in broilers by increasing the bursa size. Seyed *et al.* (2013) also reported that herbal extracts as a substitute of antibiotic reduce the oocytes of cocci in the observational birds. The other reason of recovery of MS infected birds by Chinese herbal could be due to higher digestibility of nutrients that ultimately enhance the immunity of the birds. Attia *et al.* (2017) reported that addition of herbals extracts increases the digestibility of protein, enhance growth and immunity in birds. Sultan *et al.* (2015) also reported similar results by addition of herbal extracts in broiler diet. AL-Kassie (2009) and Seyed *et al.* (2013) also observed reduction in the microbial load in gut and enhanced immunity in birds by providing *Rheum rhabarbarum*, *Lysimachia davurica* and *Codonopsis pilosula* leaf extracts in drinking water.

The recovery of MS in chicken model could be explained by bacteriostatic activity of Chinese herbs extracts. It has been reported that growth of bacteria is inhibited and eradicated by herbal extract because of presence of chemical like tannins compounds, saponins, flavonoids, and alkaloids (Madigan *et al.*, 2003; Tamara *et al.*, 2009; Farhat *et al.*, 2011). Based on the screening results in the current study, highest content of herbal extract was tannin. Tannin is useful to prevent the growth of microorganisms by inactivating (precipitation of enzyme protein) enzymes produced by microorganisms and inhibiting the growth of bacteria. Flavonoids another useful antibacterial and antioxidant was also found in Chinese herb extract used in the current study. Flavonoids enhance performance of immune system by accelerating production of leukocytes (antigen-eaters) and faster activation of lymphoid systems (Vance *et al.*, 2008). Chinese herb extract also contained alkaloids that are toxic to microbes and eradicate and inhibit gram-negative and gram-positive bacteria.

## Conclusions

Based on findings, it is concluded that the chickens receiving Chinese herbs extract of *Rheum rhabarbarum*, *Lysimachia davurica*, *Lonicera japonica*, *Codonopsis pilosula* and *Radix liquiritiae* supplementation in drinking water @ 2mL/bird/day for 3 days successfully recover from *Mycoplasma synoviae* infection. Therefore, the extracts of these Chinese herbs extract have an antibacterial potential and can be used as an alternative of antibiotics against *Mycoplasma synoviae* in chicken.

## Acknowledgements

The first author acknowledges the financial grant from Ningxia university, Yinchuan, Ningxia, China.

## References

- Amna, O.F., H. Nooraain, A. Noriham, A. Azizah and R.N. Husna, 2013. Acute and oral subacute toxicity study of ethanolic extract of *Cosmos caudatus* leaf in Sprague Dawley rats. *Intl. J. Biol. Sci.*, 3: 301–305
- Angulo, F.J., P. Collignon, J.H. Powers, T.M. Chiller, A. Aidara-Kane and F.M. Aarestrup, 2009. World Health Organization ranking of antimicrobials according to their importance in human medicine: a critical step for developing risk management strategies for the use of antimicrobials in food production animals. *Clin. Infect. Dis.*, 49: 132–141
- Attia, G., E. El-Eraky, M. Hassanein, M. El-Gamal, A. Farahat and H. Santana, 2017. Effect of dietary inclusion of a plant extract blend on broiler growth performance, nutrient digestibility, caecal microflora and intestinal histomorphology. *Intl. J. Poult. Sci.*, 16: 344–353
- Al-Kassie, G.A.M., 2009. Influence of two plant extracts derived from thyme and cinnamon on broiler performance. *Pak. Vet. J.*, 29: 169–173
- Ayorinde, D.A., M.O.I. Olusegun, O.O. Abimbola, M.S. Olajide and O.O. Oladapo, 2017. Haematological and serum biochemical parameters of broiler chickens fed varying dietary levels of fermented castor oil seed meal (*Ricinus communis* L.) and different methionine sources in south western Nigeria. *J. Poult. Res.*, 14: 5–12
- Ding, M., F. Lu and X. Yin, 2015. Rapid detection of *Mycoplasma Synoviae* in chickens by PCR. *J. Chin. Poult.*, 19: 68–70
- Farhat, A.K., H. Iqbal, F. Shahid, A. Majed, A. Muhammad and I.U. Rehman, 2011. Phytochemical Screening of Some Pakistani Medicinal Plants. *Middle-east J. Sci. Res.*, 8: 575–578
- Fennell, C.W., K.L. Lindsey, L.J. McGaw, S.G. Sparg, G.I. Stafford and E.E. Elgorashi, 2004. Assessing African medicinal plants for efficacy and safety: pharmacological screening and toxicology. *J. Ethno.*, 94: 205–217
- Fu, C., Y. Zhang, Q. Jing, T. Shi, X. Wei and X. Liu, 2018. Effect of Chinese herbal medicine on growth performance, immune organ index and antioxidant functions in broiler chickens. *Intl. J. Agric. Biol.*, 20: 1677–1681
- Gong, J., F. Yin, Y. Hou and Y. Yin, 2014. Review: Chinese herbal as alternatives to antibiotics in feed for swine and poultry production: Potential and challenges in application. *Can. J. Anim. Sci.*, 51: 141–175
- Hall, R.L., 2001. Principles of clinical pathology for toxicology studies. In: Hayes WA, Editor. *Principles and Methods of Toxicology*, 4<sup>th</sup> edition, pp: 1001–1038. Taylor and Francis (eds.). Philadelphia
- Idris, B., S.B Abdulmenem, M. Yasser, B. Tabana, A.M. Majed, M. Roziathanim and Z.A. Mohammad, 2016. Acute and sub-acute toxicity evaluation of the methanolic extract of *Alstonia scholaris* stem bark. *Med. Sci.*, 9: 2565–2570
- Konan, N., E. Bacchi, N. Lincopan, S. Varela and A. Veranda, 2007. Acute, subacute toxicity and genotoxic effect of a hydroethanolic extract of the cashew (*Anacardium occidentale* L.). *J. Eentomol.*, 110: 30–38
- Lauderdale, T.L., Y.R. Shiau, H.Y. Wang, J.F. Lai, I.W. Huang, P.C. Chen, H.Y. Chen, S.S. Lai, Y.F. Liu and M. Ho, 2007. Effect of banning vancomycin analogue avoparcin on vancomycin resistant enterococci in chicken farms in Taiwan. *Environ. Microbiol.* 9: 819–823
- Madigan, M.T., M.M John and P. Jack, 2003. *Brock Biology of Microorganisms*, pp: 704–705. International edition. Pearson education Inc. United States of America, Page 699
- Muhammad, A.U., C.Q. Xia and B. Cao, 2019. Nutrient intake, feeding patterns and abnormal behavior of growing bulls fed different concentrate levels and a single fiber source (corn stover silage). *J. Vet. Behav.*, <https://doi.org/10.1016/j.jveb.2019.03.003>
- Mushtaq, A.M., A.B. Showkat, F. Bilquees, B.A. Sheikh, S. Sidiqi and S. Pumima, 2016. *Rheum emodi* as valuable medicinal plant. *Intl. J. Gen. Med. Pharm.*, 5: 2319–4006
- Okoye, T.C., P.A. Akah, A.C. Ezike, M.O. Okoye, C.A. Onyeto, F. Ndukwu, E. Ohaegbulam and L. Ikele L, 2012. Evaluation of the acute and sub-acute toxicity of *Annona senegalensis* root bark extracts. *Asian Pac. J. Trop. Med.*, 5: 277–282
- Olson, N.O., H.E. Adler and A. Damassa, 2004. The effect of intranasal exposure to *Mycoplasma synoviae* and infectious bronchitis on development of lesions and agglutinins. *J. Avian Dis.*, 8: 623–631
- Qamar, S.H., Q. Zeng, X. Ding, S. Bai, J. Wang, Y. Xuan, Q. Zhou, Z. Su and K. Zhang, 2019. Effect of oil supplementation on growth performance, meat quality and anti-oxidative ability in meat ducks fed a diet containing aging corn. *Intl. J. Agric. Biol.*, 21: 201–208
- Rahman, A.U., C.Q. Xia, S. Huawei and B. Cao, 2017. Effects of hay grass level and its physical form (full length vs. chopped) on standing time, drinking time, and social behavior of calves. *J. Vet. Behav.*, 21: 7–12
- Rhiouani, H., J. El-Hilaly, Z.H. Israili and B. Lyoussi, 2008. Acute and sub-chronic toxicity of an aqueous extract of the leaves of *Herniaria glabra* in rodents. *J. Epidemiol.*, 118: 378–86
- Sankhari, J.M., R.N. Jadeja, M.C. Thounaojam and R.V. Devkar, 2010. Safety evaluation of *Eugenia jambolana* seed extract. *Asian Pac. J. Trop. Med.*, 53: 27–32
- Satyanarayana, P.S., D. Singh and K. Chopra, 2001. Quercetin, a bioflavonoid, protects against oxidative stress-related renal dysfunction by cyclosporine in rats. *J. Exp. Clin. Pharmacol.*, 23: 175–181
- Senthilnathan, G., S. Shenbagam and T. Suryanarayana, 2015. Isolation and molecular confirmation of *Mycoplasma Synoviae* infection from broiler breeder farms in Tamilnadu. *Ind. J. Anim. Res.*, 49: 91–94
- Seyed, D., Sharifi, H. Saeedeh, A.A. Khorsandi, Khadem, S. Abdolreza and M. Hamidreza, 2013. The effect of four medicinal plants on the performance, blood biochemical traits and ilea microflora of broiler chicks. *J. Vet. Arch.*, 83: 69–80
- Sultan, M., R. Atif, Y. Muhammad, A. Pervez, A. Ghulam, H. Khawar, M. Aisha and K.S. Muhammad, 2015. Comparative efficacy of different herbal plant's leaf extract on haematology, intestinal histomorphology and nutrient digestibility in broilers. *Adv. Zool. Bot.*, 3: 11–16
- Tamara, F., V. Mojca, S. Janez and R. Vida, 2009. Use of herbal and spices and their extracts in animal nutrition. *Acta. Argic. Sloven.*, 2: 95–102
- Vance, A., S. Branton, S. Collier, P. Gerald and E. Peebles, 2008. Effects of pre-lay ts11-strain *Mycoplasma gallisepticum* inoculation and time specific F-strain *Mycoplasma gallisepticum* inoculation overlays on internal egg and eggshell characteristics of commercial laying hens. *Poult. Sci.*, 87: 1358–1363

(Received 09 January 2019; Accepted 25 April 2019)